HAWAI'I MEDICAL JOURNAL

January 2006 Volume 65, No. 1 ISSN: 0017-8594

1, 2 & 3-BEDROOM RESIDENCES AVAILABLE

Keola La`i is life as it should be. Casual and comfortable. Simple and practical. Experience magnificent floor to ceiling windows overlooking Honolulu, as well as open dining and living areas that offer the perfect setting to entertain guests or relax in solitude. Whether you choose a 1, 2, or 3-bedroom fee simple condominium, you'll appreciate each spacious room.

Stop by the Keola La'i model today and discover everything it has to offer.

- 1 bedrooms from the mid $400,000's
- 2 bedrooms from the high $500,000's
- 3 bedrooms from the low $1,000,000's

INTERIOR FINISHES

- Separate dining area
- Floor to ceiling double paned glass
- Individually controlled central air conditioning
- Broadband connectivity
- 8' 6" high ceilings

KITCHEN FINISHES

- Polished granite countertop
- Natural maple style cabinets with glass door accents
- Italian porcelain flooring
- Stainless steel side by side refrigerator/freezer
- Stainless steel finish self-cleaning oven with ceramic glass cooktop
- Stainless steel finish microwave/hood
- Stainless steel finish quiet dishwasher

BATHROOM FINISHES

- Tigerskin yellow granite countertop
- Natural maple style cabinets
- Italian porcelain flooring

KEOLA LA'I SALES CENTER

676 Queen St., Honolulu, HI 96813

HOURS
Tuesday – Sunday, 10 am to 6 pm
Monday, Noon to 6 pm

Courtesy to Brokers:
Broker must accompany client on first visit.
Price subject to change and availability.

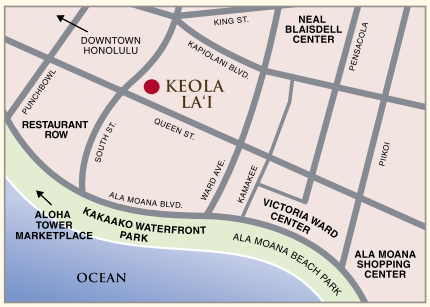

KEOLA LA'I
GATEWAY TO THE NEW KAKAAKO

Phone (808) 591-9600
Fax: (808) 591-9663
Website: www.keolalai.com
email: info@keolalai.com

A&B Kakaako LLC
Developer
A&B Properties Inc., a subsidiary of Alexander & Baldwin, Inc., is the manager of A&B Kakaako LLC.

Coldwell Bankers
Pacific Properties
Project Broker
1314 S. King Street., 2nd Floor, Honolulu, HI 96814

HAWAI'I MEDICAL JOURNAL
(USPS 237-640)

Published monthly by the
Hawai'i Medical Association
Incorporated in 1856 under the Monarchy
1360 South Beretania, Suite 200
Honolulu, Hawaii 96814-1520
Phone (808) 536-7702; Fax (808) 528-2376

Editors
Editor: S. Kalani Brady MD
Editor Emeritus: Norman Goldstein MD
Contributing Editor: Russell T. Stodd MD

Editorial Board
John Breinich MLS, Satoru Izutsu PhD,
Douglas G. Massey MD, Myron E. Shirasu MD,
Frank L. Tabrah MD, Alfred D. Morris MD

Journal Staff
Editorial Assistant: Drake Chinen

Officers
President: Patricia Lanoie Blanchette MD
President-Elect: Linda Rasmussen MD
Secretary: Thomas Kosasa MD
Treasurer: Calvin Wong MD
Immediate Past President: Inam Ur Rahman MD

County Presidents
Hawaii: Jo-Ann Sarubi MD
Honolulu: John Rausch MD
Maui: Howard Barbarosh MD
West Hawaii: Kevin Kunz MD
Kauai: Christopher Jordan MD

Advertising Representative
Roth Communications
2040 Alewa Drive
Honolulu, Hawaii 96817
Phone (808) 595-4124
Fax (808) 595-5087

The *Journal* cannot be held responsible for opinions expressed in papers, discussion, communications or advertisements. The advertising policy of the *Hawai'i Medical Journal* is governed by the rules of the Council on Drugs of the American Medical Association. The right is reserved to reject material submitted for editorial or advertising columns. The *Hawai'i Medical Journal* (USPS 237640) is published monthly by the Hawai'i Medical Association (ISSN 0017-8594), 1360 South Beretania Street, Suite 200, Honolulu, Hawai'i 96814-1520.

Postmaster: Send address changes to the *Hawai'i Medical Journal*, 1360 South Beretania Street, Suite 200, Honolulu, Hawai'i 96814. Periodical postage paid at Honolulu, Hawai'i.

Nonmember subscriptions are $25. Copyright 2006 by the Hawai'i Medical Association. Printed in the U.S.

Contents

He Mana'o, Thoughts from the Editor: 'Akahi – #1
S. Kalani Brady MD, MPH, FACP 4

Editor Emeritus: A Great Decade & Nails and Numbers
Norman Goldstein MD, FACP 6

Special Contribution: Cell Phones Don't Cause Tumors. From the United Kingdom Institute of Cancer Research.
Frank Tabrah MD 8

Special Contribution: The Medicinal Leech
Maxwell Urata MD 9

Commentary: Fred Holschuh MD, appointed to the National Association of Counties (NACo) Methamphetamine Action Group 10

Commentary: North Hawai'i Community Hospital Receives American Heart Association Performance Achievement Award 10

Fatal pulmonary *Mycobacterium abscessus* infection in a patient using etanercept
John E. Thomas MD, Christy R. Taoka MD, Barnett T. Gibbs MD, and Susan L. Fraser MD 12

Severe Vitamin D Deficiency in Hawai'i: A Case Report
Michael Bornemann MD, FACP, FACE 16

An Unusual Abdominal Tumor – Leiomyosarcoma of the Mesentery: A Case Report
Catherine J. Simonovich MS4, John M. Hardman MD, James J. Navin MD, Jennifer Jacobs MD and Neil Fergusson MD 18

Residents' Case Series: Case Report: A 17-year-old Female with Headache and Fever
John Misailidis MD, Anna Dodd MD, Douglas Kwock MD, and Dominic Chow MD 21

Medical School Hotline: Department of Pediatrics at the John A. Burns School of Medicine (JABSOM) 2004-2005 Update
Raul C. Rudoy MD 25

Cancer Research Center Hotline: Risk Factors for Pancreatic Cancer in the Hawai'i – Los Angeles Multiethnic Cohort Study
Ute Nöthlings DrPH and Laurence N. Kolonel MD, PhD 26

Classified Notices 29

Weathervane
Russell T. Stodd MD 30

Cover art by Dietrich Varez, Volcano, Hawai'i. All rights reserved by the artist.

"Lā'ieikawai"

Depicting the legendary mythological girl with her friendly birds.

HE MANA'O: THOUGHTS FROM THE EDITOR

HAWAI'I MEDICAL JOURNAL

'Akahi – #1

It was not a surprise that Norm Goldstein called me in late November 2005. I have been fortunate to call him friend for nearly two decades. He proposed me to the St. Andrew Society in the late 1990's, and later he and his wife Ramsay proposed me to the National Society of Arts and Letters. It was Norm to whom I turned for counsel on the name of a tattoo artist four years ago, as he has probably the largest collection of tattoo photographs in medicine. We had worked together on a number of projects, both medical and other, over the years.

S. Kalani Brady MD, MPH, FACP
Editor, Hawai'i Medical Journal

It was a surprise, however, when he explained that he needed to end his decade as editor for the Hawai'i Medical Journal. He explained that despite a fine efficient staff, he needed to reclaim the time he spent as editor to pursue other life goals that had been tabled for too long. He stated he intends to complete a book and several additional book chapters that he has been requested to submit. Further, he has other personal goals. Norm is a persuasive man. I told him I would consider the commitment. He continued to encourage me to accept the position. My trepidation lay in trying to follow in the footsteps of not only Norm Goldstein, but Frederick Reppun, Henry Yokoyama, and Harry Arnold. But he prevailed, and I agreed to attempt to fill his large shoes. I spoke extensively with Dr. Pat Blanchette, President of the Hawai'i Medical Association, and Paula Arcena, its Executive Director, and at the December meeting of the HMA Council was ratified as the new editor.

Thus, I ask you to allow me to introduce myself. I am Hawaiian, Portuguese, and Caucasian. My Hawaiian family is Keli'ikanaka'oleaipoalani, mostly from Waimea and Kekaha, Kaua'i, although after spending my early childhood in various areas of this country and Germany as a military dependent, I was raised in Kailua, O'ahu. My Caucasian roots are in New England, where my family arrived in 1623 to become part of the Massachusetts Bay Colony, helping to found Harvard College, and later fighting for independence from England. My direct ancestors settled in southeastern Connecticut and Rhode Island, many becoming sailors (including whalers) and missionaries (thus my Hawaiian roots).

While an eighth grade student at St. Anthony's School in Kailua, as part of a Boy Scout project, I became a weekly columnist for the Pali Press, which later became the Windward Press. During this period, I also contributed occasional articles to the Honolulu newspapers. At Harvard College, I minored in English, but clearly hoped for a career as a physician. During the mid 1980's, Dr. Yokoyama asked me to kokua with the Hawai'i Medical Journal, and for several years I produced a column, "Over the Editor's Desk".

As many of you may know, most of my communications experience is in a different medium, television. For the past 10 years, I have co-hosted a weekly segment on the KHON-2 morning news called "Ask the Doctor". For two years, I co-hosted the weekly talk show "Health in Paradise" on 'Olelo Channel 52, and this past fall hosted the weekly medical presentation "UH on Call" on PBS Channel 10.

For the past two and a half years, I have served as Associate Professor and Vice-Chair of the Department of Native Hawaiian Health at the University of Hawai'i John A. Burns School of Medicine. I am fortunate to lead a team of physicians who care for the Hansen's Disease patients in Kalaupapa, where I spend one to two days weekly. I also serve as the Director of Education for the Straub Foundation, a non-profit entity committed to both professional and public education about health improvement.

I am grateful for the stability of the Journal and its fine staff, contributing editors, and columnists, and will do my best to serve them and you, the readers! Aloha e.

The HMJ is published monthly by the Hawai'i Medical Association. Incorporated in 1856 under the Monarchy.

Over 50 Years of....

...Dedication to Hawaii's Physicians!

The Board of Directors at Physicians Exchange of Honolulu invite you to experience the only service designed by and for Physicians in Hawaii.

President: Franklin Young M.D.

Vice President: Garret Yoshimi

Treasurer: Stephen Bugman

Secretary: Richard Ando Jr. M.D.

Directors:

Linda Chiu M.D.

Stephen Kemble M.D.

Calvin Wong M.D.

Ann Barbara Yee M.D.

Robert Marvit M.D.

- **Professional 24 Hour Live Answering Service**
- **Relaying of Text Messages to Pagers and Cell Phones**
- **All Calls Confirmed, Documented and Stored for 7 Years**
- **HIPAA Compliant**
- **Affordable Rates**
- **Paperless Messaging**
- **Receptionist Services**
- **Subsidiary of Honolulu County Medical Society**
- **Discount for Hawaii Medical Association members**

Discover the difference of a professional answering service. Call today for more information.

Physicians Exchange of Honolulu, Inc.
1360 S. Beretania Street, #301
Honolulu, HI 96814

524-2575

Franklin Young MD
President

Garret Yoshimi
Vice-President

Richard Ando Jr. MD
Secretary

Stephen Bugman, Treasurer (not pictured)

Linda Chiu MD
Director

Stephen Kemble MD
Director

Calvin Wong MD
Director

Ann Barbara Yee MD
Director

Robert Marvit MD
Director

Rose Hamura
Manager

HAWAI'I MEDICAL JOURNAL

A GREAT DECADE

Norman Goldstein MD, FACP Laureate
Editor Emeritus, Hawai'i Medical Journal

TEN YEARS AGO as a member of the Journal Board, I received a call from Editor J. Frederick Reppun MD, who explained that he could "no longer keep up" the Journal and that the Hawai'i Medical Association was planning to suspend its publication. However, the Journal is mandated to be published in the Association bylaws, so we could either attempt to change the 100-year-old law or keep the Journal in operation. Neither of us liked the idea of abandoning it, so rather apologetically, Fred asked if I could manage to do it. "I'm too busy, Fred, but for you I'll do it," and soon I was surrounded by bankers boxes filled with correspondence, accepted and rejected manuscripts, and assorted back issues.

There were already monthly columns in place. To them I added regular submissions from the Cancer Research Center, Tripler Army Medical Center, our Medical School, and medical and surgical residents.

A nucleus of contributing editors agreed to stay on, including Henry Yokoyama MD, who passed away earlier this year. His widow, Marjie, with family and friends, founded the Henry Yokoyama fund administered by the Hawai'i Medical Foundation, to help support the Journal. Through the years I've worked very closely with John Breinich and the staff of the Hawai'i Medical Library, who supply valuable references sometimes in a matter of minutes via fax. They continue to index the Journal every year.

For 2006, a funding request from the Association has been approved. I've spoken with Tom Kosasa MD, suggesting that the Pan Pacific Surgical Association become a sponsor of the Journal. He agreed. Perhaps in the coming year, the Hawai'i Chapters of the American College of Physicians and the American College of Surgeons could do the same. I envision their logos diminutively sized and placed discretely on future covers. Artist Dietrich Varez, who has provided covers during my editorship, promises to continue.

It has been a sincere pleasure serving as Editor of the Hawai'i Medical Journal during a great decade. With everything in order, this seems a propitious time to demit to an outstanding and energetic colleague, Kalani Brady MD, who has accepted my singular nomination to assume the position of Editor beginning with this first issue of the new year. The HMA Executive Council approved his appointment in December.

Although we in Hawai'i know that smooth sailing is never assured, with Kalani at the helm, Russ Stodd's insightful Weather Vanes, Drake Chinen keeping us on course, Michael Roth providing the staples of advertising revenue, and through the support of Pat Blanchette MD, President of the Hawai'i Medical Association, the USS Hawai'i Medical Journal is set to embark on an educational cruise. We wish the crew Bon Voyage.

Editorial
Nails and Numbers...

Nail. One of the thin, horny, translucent plates covering the dorsal surface of the distal end of each terminal phalanx of fingers and toes. A nail consists of corpus or body, the visible part, and radix or root at the proximal end concealed under a fold of skin. The under part of the nail is formed from the stratum germinativum of the epidermis, the free surface from the stratum lucidum, the thin cuticular fold overlapping the lunula representing the stratum corneum.

Stedman's Medical Dictionary goes on to include definitions of eggshell nail, half & half nail, Hippocratic nail, ingrown nail, Küntscher nail (with illustrations), parrot-beak nail, pincer nail and a half-dozen more nail adjectives.

F1	Left Hand, Second Digit	T1	Left Foot, Second Digit
F2	Left Hand, Third Digit	T2	Left Foot, Third Digit
F3	Left Hand, Fourth Digit	T3	Left Foot, Fourth Digit
F4	Left Hand, Fifth Digit	T4	Left Foot, Fifth Digit
F5	Right Hand, Thumb	T5	Right Foot, Great Toe
F6	Right Hand, Second Digit	T6	Right Foot, Second Digit
F7	Right Hand, Third Digit	T7	Right Foot, Third Digit
F8	Right Hand, Fourth Digit	T8	Right Foot, Fourth Digit
F9	Right Hand, Fifth Digit	T9	Right Foot, Fifth Digit
FA	Left Hand Thumb	TA	Left Foot, Great Toe

Most of us have 10 on our fingers and 10 on our toes. Most of us describe these horny plates as thumb, index, middle, ring finger and pinky on the right and left hands. On the feet, we have big toes followed by the 2nd, 3rd, 4th & 5th.

In today's computerized world, we understand the need for a numbering system for recording specific digits rather than spelling out "index finger" or "pinky," but the numbering system adopted by the Health Care Common Procedure Coding System (HCPCS/ National) and approved for hospital outpatient use defies logic:

According to the Thirteenth Edition of the Medicode HCPCS Level I, this Code Book was "created by the industry's leading experts."

In trying to understand the nonsensical numbering system for finger and toe nails, I contacted various nail authorities, locally, nationally and internationally.

Typical of the response to my queries was that received from Antonelli Tosti, M.D. of Bologna, Italy, past president of the Council for Nail Disorders, who wrote:

> *"Dear Professor Goldstein,*
> *Thank you for your letter about the modifiers approved for Hospital Outpatient Uses Level I, and I agree with you the numbering system makes no sense!!! It is also very complicated."*

One final thought, why are morgue toe tags always placed on the Right Foot Great Toe ["T5"] ?

Diagram of Nail Numbers

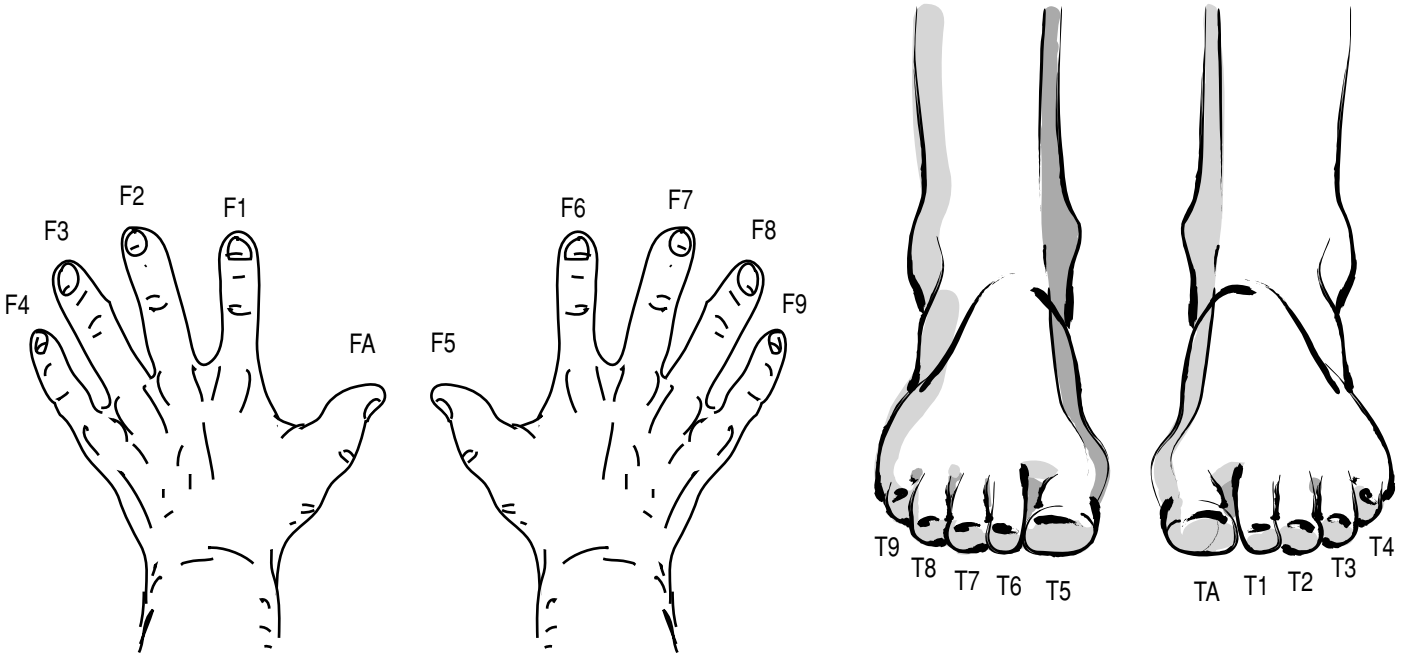

SPECIAL CONTRIBUTION

Cell Phones Don't Cause Tumors. From the United Kingdom Institute of Cancer Research. By Frank Tabrah MD

I have had many inquiries about the possible role of cell phone energy output in head, neck or brain tumors. Here is a report from the UK Institute of Cancer Research that confirms information from the Bioelectromagnetic Society – it looks like a non-problem…..FLT

"Study Finds No substantial risk in first decade of use, researcher says." By James Niccolai, IDG News Service, Wednesday, August 31, 2005.

Using a mobile phone for 10 years does not significantly increase a person's risk of developing a tumor, according to a new study from the UK's Institute of Cancer Research.

The investigation was the largest one to date that has studied the relationship between mobile phones and acoustic neuromas, a type of tumor that occurs close to the ear, according to the study's authors.

The study looked at 678 people with acoustic neuromas and 3,335 people without illness. They were asked detailed questions about their mobile phone use, including the length and frequency of the calls they made, the type of phone they used, and other factors that might affect their risk of getting the disease.

The study found no relation between risk of acoustic neuromas and level of mobile phone use.

Tumor Appearances

Acoustic neuromas are of particular interest because they occur close to where mobile phones are held to the head. They are a type of benign tumor that grows in the nerve connecting the ear to the brain. Acoustic neuromas often cause hearing loss and impair balance, but they do not typically spread to other parts of the body.

The study's results corroborate the findings of other reports, but since it recommends longer-term studies, the UK investigation may not put to rest the debate over whether cell phone radiation harms health.

Still, the test marks "a great step forward" in understanding the relationship between tumors and mobile phones because it involved such a large number of participants, the researchers said.

"The evidence for the health effects of mobile phones and radio-frequency fields in general has been reviewed by several expert committees quite recently, and the results of this new study are compatible with their conclusions," Minouk Shoemaker, one of the report's authors, wrote in an e-mail response to questions.

The study was published online in the British Journal of Cancer. It was conducted in the United Kingdom, Denmark, Finland, Norway and Sweden – countries where mobile phones were introduced relatively early.

A separate study from Denmark, published in April in the journal Neurology, looked at two other types of tumor: glioma and meningioma. That study involved about 1,200 participants, including 427 who suffered from one of the two diseases; it too, found no increased risk of tumor development from cell phone use. Like the UK report, it advised that longer-term research be undertaken.

A further report released in January by the UK's National Radiological Protection Board acknowledged the absence of any conclusive evidence linking mobile phones to tumors or cancer; nevertheless it recommended that children's mobile phone use be limited, suggesting that they might be more vulnerable to the radio frequency radiation exposure because their nervous systems are still developing.

Children Not Studied

This week's UK study looked at people between the ages of 18 and 69, and did not address the risks to children, Shoemaker said.

The Institute of Cancer Research is also studying other types of tumors, including glioma and meningioma. Results from those tests are not yet ready for release, she said.

Asked for her personal opinion about whether mobile phones pose a health risk, she replied that the greatest health risk established to date involves the increased risk of accidents due to using a cell phone while driving.

EDITOR EMERITUS' NOTE

Frank Tabrah, M.D., serves on the Editorial Board of the Hawai'i Medical Journal and works in the Pediatric and Undersea Medicine Department of Straub Clinic and Hospital. This article appeared in the October 2005 issue of Straub Conversations and is reproduced with permission.

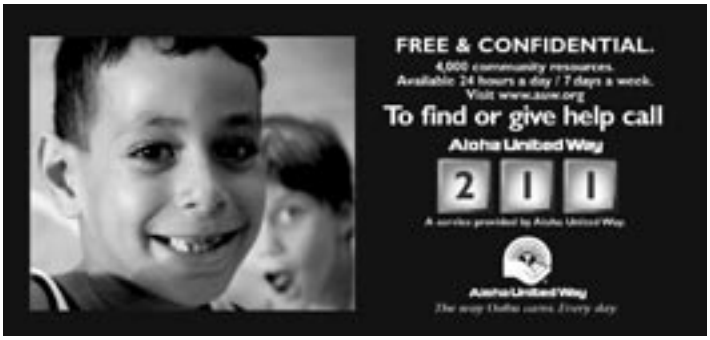

SPECIAL CONTRIBUTION

The Medicinal Leech. By Maxwell Urata MD

I was in Boston the summer after my freshman year in med school. One Sunday while taking a stroll I noticed a small walkdown store advertising unusual remedies on its sign hanging at street level. One of the items was leeches. Being Sunday in Boston, it wasn't open. I've never seen a leech, much less the medicinal leech which this must have been.

Leeches have been used for centuries in medical applications. The FDA approved its use as a "medical device" in the summer of 2004. This article is a distillation of an article in *The New Yorker* of July 25, 2005.

Because leeches are such a specialized organism, it is difficult to believe that they are found, literally, in almost all habitats. Some leeches live on the blood of mammals. Some of the highly specialized ones live in the nose of camels, in the Sahara of all places, in the "anus" of hippopotami, and suck on the blood of bats. There are 650 species of leeches discovered thus far but the only one that is felt suitable for human medicinal use is *Hirudo medicinalis*. It was originally found in the lakes and streams of Europe but are rarely found there now because of over harvesting during the early to mid 1800s when leeching patients became a craze. Leeching was supposed to cure everything including obesity and nymphomania.

In Paris alone, six million leeches were used in one year in the mid-1800s. Collecting these massive numbers required ingenuity. Young women were recruited to wade into leech rich waters where the leeches would attach themselves to their bare legs. When this was not sufficient to meet the demand, in the Gironde, 20,000 horses were driven into the marshes yearly to collect leeches on their skin. Many bled to death. Due to this overharvesting, leeches became extinct in Germany, for example, at the end of the 19th century. With the advent of the discovery of germs as a cause of illness and Sir William Osler's textbook promoting the germ theory, leeches finally lost their popularity.

It was not painful to be "leeched." The leech secretes an anesthetic in its saliva as well as a powerful anticoagulant. But it must not have been pleasant. A favorite spot to attach leeches seems to have been the nose. Leeches before feeding are 2-4" long. When engorged with blood, they became bloated and hung down from the nose to the mouth making eating difficult, and probably looking fairly disgusting. Because of the anticoagulant produced by the leech, the attachment point would continue to bleed for several hours after the leech had been detached.

The primary producer of medicinal leeches for Great Britain and the United States is Biopharm, located in England. It was founded by Roy T. Sawyer, an American and probably the world's foremost authority on leeches, who has written an exhaustive 3-volume reference on leeches. The modern use of leeches was slow initially, but a breakthrough event occurred in 1985. A 5-year-old boy had had his ear torn off by a dog, and although the ear had been reattached by a microsurgeon named John Upton, the ear became congested and blue. The venous drainage, being a low pressure system, did not open up right away. He obtained a few leeches from Biopharm and attached them to the most congested areas of the ear. The ear pinked up as the leeches fed. The ear was saved. The story was picked up by the news services and interest was immediate from the microsurgery community. The author of the article states that the use of leeches has become a part of the curriculum of training of reconstructive plastic surgeons. It is useful in venous congestion in digit and limb reattachment, scalp implants, breast reconstruction. It is used only as a last resort, but has proven to be the ace in the hole when needed.

Why are leeches so effective in reducing congestion in operated areas? The medicinal leech has three sets of fine teeth in jaws arranged in a "Y" configuration. When it feeds, it saws into the skin and releases the anesthetic in its saliva as well as a powerful anticoagulant , a vasodilator to open the vessels and increase blood flow, and a spreading factor. Hyaluronidase has been isolated from leech sputum. The combination of these chemicals and enzymes allows the chemicals to spread far from its attachment point, liquefying any coagulated blood. The leech, as it feeds, becomes bloated and about seven to 11 times its normal size. After about 20 minutes, sometimes more, sometimes less, it is sated and detaches itself. The amount of blood removed is about two to three teaspoons, or 10 to 15 milliliters. Due to the chemicals released, the bite continues to bleed and continues to drain the congestion. Depending on the amount of clot, multiple leeches may have to be utilized. In the wild, leeches feed about once a year. But medicinal leeches are destroyed humanely "like a used syringe and needle."

Sawyer is doing research into what components are in leech saliva. He has found some promising compounds that might have uses in ophthalmology, heart disease, and in helping antibacterials to be more effective. Other researchers have found leech application to be useful in arthritis, of all things.

One interesting fact is that there is a giant Amazon leech. It was felt to be mythical, but Sawyer's group rediscovered it in the coastal marshes of French Guiana. Reportedly as long as a man's forearm, the first specimen they discovered was 18 inches long with a 6-inch long "needlelike proboscis" which it inserts into its host. A French scientist describing it 50 years ago stated that a few of these feeding from a cow or horse were sufficient to kill the animal.

*See **The Medicinal Leech**, p. 11*

COMMENTARIES

Fred Holschuh MD, appointed to the National Association of Counties (NACo) Methamphetamine Action Group

Hawai'i County Council Chair Stacy Higa announced the appointment of Fred Holschuh MD to the NACo Group at the September 21, 2005 Council meeting. Dr. Holschuh attended all the methamphetamine meetings at the July NACo national meeting in Honolulu, and was appointed by NACo president, Bill Hansell, to the Action Group in a letter dated August 25, 2005 to Chair Higa.

Hansell has made his presidential initiative clear: To embolden the battle against what the National Association of Counties considers *America's most serious public health issue; the manufacturing, importation and use of methamphetamine*.

Dr. Holschuh brings to the NACo group 30 years of emergency medicine experience in Hawai'i mostly in Hilo; and many years of experience with methamphetamine users and the victims of the crimes and acts of violence the drug can produce. "Methamphetamine is extremely addictive, and its use can cause numerous medical and psychiatric conditions in the users, including death, and can produce levels of violence against strangers, partners and children that is at times beyond belief," said Dr. Holschuh. "To be asked to be a part of this national Methamphetamine Action Group means so much more than merely a new opportunity to attack this crisis, it is an obligation I feel very deeply about."

Dr. Holschuh, a co-founder of Hawai'i Emergency Physicians Associated in 1971, has been a member of numerous boards and commissions involving substance abuse, impaired driving, tobacco control, HIV/AIDS, domestic violence, child abuse, EMS, and trauma. He is a past president of the Hawai'i Medical Association, past Physician of the Year, and was a member of the Hawai'i delegation to the American Medical Association.

Holschuh, who is in his second term as a member of the Hawai'i County Council, will be making contact with the AMA Board of Trustees to request consideration of collaborating with NACo on this important national problem.

"Time is truly of the essence in this instance," said Dr. Holschuh.

"Each day that passes by we lose more and more people to this deplorable and destructive substance."

"Dr. Holschuh's association with this action group will truly benefit Hawai'i and the County of Hawai'i," said Chairman Higa. "I know he will represent us very well."

North Hawai'i Community Hospital Receives American Heart Association Performance Achievement Award

In Kamuela, Hawai'i, North Hawai'i Community Hospital has received the American Heart Association's Get With The Guidelines–Coronary Artery Disease (GWTG-CAD) Initial Performance Achievement Award. The award recognizes North Hawai'i Community Hospital's commitment to quality and success in implementing the highest standards of cardiac care shown to effectively improve treatment of patients hospitalized with coronary artery disease. The hospital is the first in Hawai'i and one of only 36 hospitals in the United States to receive this distinction.

"We feel extremely honored to have been recognized by the American Heart Association in this way," said Stan Berry, chief executive officer of North Hawai'i Community Hospital. "This achievement could not have been done without our hardworking staff and physicians and their commitment to the Get With the Guidelines program."

To receive the award, North Hawai'i Community Hospital consistently complied with the GWTG-CAD program requirements for three months. Under the program, patients are started on aggressive risk reduction therapies such as cholesterol-lowering drugs, aspirin, ACE inhibitors and beta-blockers in the hospital and receive smoking cessation and weight management counseling before they are discharged. Hospitals that receive the award have demonstrated that at least 85 percent of their coronary patients (without contraindications) are discharged following the American Heart Association's recommended treatments.

"North Hawai'i Community Hospital is dedicated to offering our patients the highest quality of cardiac care, and the American Heart Association's Get With The Guidelines program is helping us accomplish this by making it easier for our professionals to improve the long-term outcomes of our cardiac patients," said Dr. Kenneth Riff, executive director of the Hawai'i Heart Brain Center at North Hawai'i Community Hospital. "The hospital began participating in the Get With the Guidelines program in 2003, and we have worked very hard to train our staff and to develop processes and systems to ensure that we consistently deliver state-of-the-art care. This award recognizes that we have reached that goal and that our patients receive

care that is comparable to that given at the country's top medical facilities, as we have demonstrated our compliance in following the same up-to-date treatment guidelines as those followed at the nation's best institutions."

Heart disease remains the leading cause of death in Hawai'i and in the United States, and on the Big Island it causes 25 percent more deaths than the state average. "By having their treatments initiated in the hospital, patients better understand how important the medications are to their long-term health and are more likely to remain on these life-saving therapies," said Riff. "By participating in Get With The Guidelines, we hope to reduce the number of lives that are prematurely lost to heart disease."

"The American Heart Association applauds North Hawai'i Community Hospital for its success in implementing the appropriate standards of care and protocols to reduce the number of recurrent events in coronary patients," said Dr. William Dang, the American Heart Association volunteer chairman for the Hawai'i Get With The Guidelines project. "The hospital is well above the national average in terms of implementing these life-saving treatments."

Projections have shown that implementation of cardiovascular disease secondary prevention guidelines nationwide, as promoted in the GWTG-CAD program, could result in saving more than 80,000 lives each year.

The American Heart Association's GWTG-CAD program is designed to increase the use of and adherence to the association's secondary prevention guidelines for coronary artery disease. Developed to assist healthcare professionals follow proven standards and procedures before patients are discharged, GWTG-CAD can help North Hawai'i Community Hospital reduce the risk of recurrent heart attacks and death in treated patients. The program, which works by mobilizing teams in acute care hospitals to implement American Heart Association / American College of Cardiology secondary prevention guidelines, was developed with support from an unrestricted educational grant from Merck & Co., Inc.

According to the American Heart Association, more than 450,000 people suffer recurrent heart attacks each year. Statistics also show that within one year of an attack, 25 percent of men and 38 percent of women will die. Within six years after a heart attack, about 22 percent of men and 46 percent of women will be disabled with heart failure.

North Hawai'i Community Hospital is a full-service acute-care hospital that opened in May 1996 and serves the 30,000 residents and visitors of Waimea, North Kohala, and the Hamakua and Kohala Coasts and beyond. It is a community owned non-profit hospital and is governed by a local board of directors.

The American Heart Association's Get With The Guidelines program is being implemented in hospitals around the country. For more information on Get With The Guidelines, visit www.americanheart.org/getwiththeguidelines.

The Medicinal Leech, *from p. 9*

Leeches are annelids, the segmented worms. Earthworms are annelids. They are hermaphroditic. They are also amphibious. They are perfectly at home in the water and land and can move "surprisingly fast" in either environment. Photos of *Hirudo medicinalis* reveal a rather pretty slug-like flat creature with two variegated stripes running the length of its body. It has two orifices. The one in front is the mouth and the one in back the posterior sucker which is larger. It moves by attaching its anterior sucker and pulling itself forward while releasing the posterior sucker. Its swimming motion reminds me of the lamprey.

I do know that someone in a Honolulu hospital has used a leech to save an ear. It will be interesting to see who on the KMC staff will be the first to use leeching at Kuakini.

Now, if you really want to be grossed out, read my next article on maggots.

EDITOR EMERITUS' NOTE

The above appeared in the Kuakini Health System Medical Staff Newletter August-October 2005 and reprinted with permission of the PR Department at Kuakini. Max Urata, M.D., was born in Honolulu, attended Iolani School, University of Hawai'i and went to medical school at Washington University in St. Louis, Missouri. He was in private practice of Neurosugery from 1969-1998 and is now a Medical Director at HMSA.

Aloha Laboratories, Inc
…when results count

CAP accredited laboratory
Quality and Service

David M. Amberger M.D.
"Best Doctors in America"
Laboratory Director

Phone (808) 842-6600
Fax (808) 848-0663
results@alohalabs.com
www.alohalabs.com

Fatal pulmonary *Mycobacterium abscessus* infection in a patient using etanercept

John E. Thomas MD, Christy R. Taoka MD, Barnett T. Gibbs MD, and Susan L. Fraser MD

Abstract

A case of fatal pulmonary Mycobacterium abscessus *infection in a 56-year-old man is reported. The patient had a longstanding history of seropositive, nodular rheumatoid arthritis with severe joint manifestations that had been treated with a regimen of prednisone, leflunomide, and etanercept. He presented to our facility with complaint of productive cough, persistent fevers, pleuritic chest discomfort, and dyspnea at rest.*

The patient was admitted to hospital, placed in isolation, a left-sided chest tube was inserted (left pneumothorax identified), and sputum acid-fast bacteria stains and cultures were obtained. Fluorochrome stains demonstrated numerous acid-fast bacteria, and M. abscessus *was recovered from the culture media. He was treated with a regimen of amikacin, cefoxitin, and clarithromycin. He initially responded well, and was discharged home with this regimen. He remained afebrile with decreased cough and sputum production until 15 days after discharge when he was again admitted to hospital, with acute onset dyspnea and right-sided chest discomfort (right pneumothorax identified). He ultimately expired, due to overwhelming pulmonary infection, 20 days after readmission to hospital. Autopsy revealed acid fast bacilli in the setting of numerous, bilateral, necrotic, granulomatous, cavitary pulmonary lesions.*

Based on its mechanism of action, we propose an association between the use of etanercept, a tumor necrosis factor alpha (TNF-α) inhibitor, and this case of fatal pulmonary mycobacterial infection. We recommend that physicians exercise cautious clinical judgment when initiating etanercept therapy in persons with underlying lung disease, especially in communities in which mycobacterial organisms are highly prevalent. We also advise physicians to maintain a high level of vigilance for late onset granulomatous infection in persons using etanercept.

Introduction

Rheumatoid arthritis is a disorder that results from the complex interaction of many processes which occur primarily within an affected joint. The antigen-dependent activation of T cells, by still unknown antigens in an immunologically susceptible host, is among the initial events of rheumatoid arthritis. This T cell activation leads to a cascade of further events including the activation and proliferation of synovial lining and endothelial cells, the recruitment and activation of pro-inflammatory cells from the circulation and bone marrow, the secretion of tumor necrosis factor alpha (TNF-α) and other cytokines by macrophages, and autoantibody production.

Etanercept is a recombinant tumor necrosis factor (TNF) receptor fusion protein that also targets TNF-α. In the United States, etanercept has been approved for use in patients with rheumatoid arthritis. Controlled trials have demonstrated that etanercept therapy (25mg administered subcutaneously twice weekly) can provide an initially rapid improvement in the symptoms of rheumatoid arthritis, and appears to delay the progression of radiologically evident joint erosions when compared with methotrexate.[1]

TNF-α plays a significant role in the immune response to mycobacterial infection. TNF is a requirement for the process of granuloma formation, increases the ability of macrophages to phagocytose and kill bacteria, and induces apoptosis of presumably ineffective macrophages.[2] A number of cases of pulmonary and disseminated *Mycobacterium tuberculosis* infections have been associated with the use of etanercept.[3,4,5] However, no case of pulmonary *M. abscessus* infection associated with the use of etanercept has previously been reported in the literature. We present a case of fatal pulmonary *M. abscessus* infection occurring in a 56-year-old man using etanercept as part of a multiple-drug regimen for the treatment of seropositive nodular rheumatoid arthritis. In addition, we provide a brief overview of the pharmacotherapeutic actions of etanercept and implicate it as the most likely permissive agent, based on its mechanism of action, for this case of fatal pulmonary *M. abscessus* infection.

Case Report

The patient, a 56-year-old man with an 11-year history of seropositive nodular rheumatoid arthritis (with known pulmonary involvement), had previously been intolerant to the side effects of several disease modifying anti-rheumatologic drugs including methotrexate, hydroxychloroquine, and sulfasalazine. He had experienced sub-optimal control of his disease despite

Correspondence to:
John E. Thomas MD
Department of Medicine
1 Jarrett White Road
Tripler AMC HI 96859-5000
Ph: (808) 433-4049
Fax: (808) 433-1555
E-mail: john.e.thomas1@us.army.mil

a one-year regimen of leflunomide combined with an ongoing, low dose prednisone regimen (2 mg daily). Etanercept, 25 mg administered subcutaneously two times per week, was added to the regimen resulting in significant improvement in his articular symptoms. Fifteen months after the addition of etanercept to the regimen, he presented to our facility with complaint of a one-week history of productive cough, persistent fevers, pleuritic chest discomfort, increased sputum production (with change in sputum character), and dyspnea at rest. He was initially evaluated by his primary care physician who prescribed an oral antibiotic regimen of amoxicillin/clavulanate 875/125 mg twice daily. After four days, the regimen was empirically changed to oral gatifloxacin 400 mg daily, in the setting of persistent symptoms. The patient again presented himself, after six days of antibiotic therapy, with complaints of persistent dyspnea and acute worsening of his pleuritic chest discomfort.

On examination the patient appeared mildly tachypneic. He was well nourished and in no acute distress. Vital signs included a respiratory rate of 24 per minute, and pulse oximetry was 90 percent on room air. Blood pressure was 132/89mmHg. The neck was supple with a midline trachea and was without palpable lymphadenopathy or jugular venous distension. The pulmonary exam revealed end-inspiratory wheezes and crackles at the right base as well as end-inspiratory wheezes and "popping" sounds in the left axilla. Vesicular sounds were generally distant throughout. Evaluation of his extremities revealed moderate ulnar deviation and severe, chronic nodular changes consistent with rheumatoid arthritis.

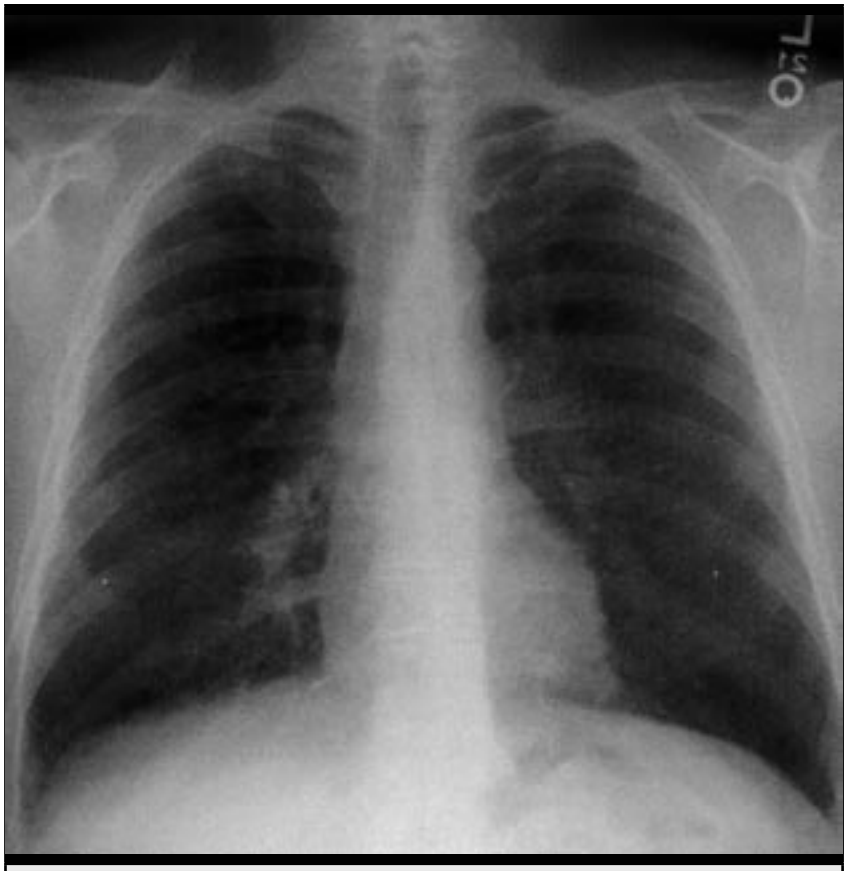

Figure 1a.— is the patient's baseline plain chest radiograph (CXR) showing a diffuse reticular nodular pattern, most prominent in the lower lobes.

Chest radiographs demonstrated extensive left pneumothorax with air surrounding the lateral, inferior, medial, and superior aspects of the left lung. (Figure 1b) Opacification of the left upper lobe, left hilum, and right lower lobe was also present. The most recent, prior chest radiograph (obtained 19 months earlier) revealed a diffuse reticular nodular pattern, more so in the lower lobes, and especially on the right (figure 1a). The baseline chest radiograph was interpreted by a staff radiologist as "possibly consistent with lung involvement secondary to rheumatoid arthritis".

The patient was admitted to hospital, placed in respiratory isolation (*M. tuberculosis* was considered in the differential diagnosis), and a left-sided chest tube was inserted. Sputum gram stain revealed no microorganisms; however, sputum fluorochrome stains revealed moderate to numerous acid-fast bacteria. *M. tuberculosis* was ruled out using the Gen-probe 49 amplified mycobacterium tuberculosis direct test. On hospital day number six, rapidly growing mycobacteria were isolated, and by hospital day number eight, *Mycobacterium chelonae-abscessus* complex was identified (Focus Technologies). Further speciation was performed by the National Jewish Medical and Research Center resulting in the identification of *Myocobacterium abscessus* as the pathogenic organism. The isolate was sensitive to amikacin, kanamycin, cefoxitin, clarithromycin, and azithromycin.

Etanercept was discontinued upon admission to hospital and a tuberculin skin test (TST) was performed (without reaction after 48 hours; no prior TST documented). His outpatient leflunomide regimen was continued. Prednisone was increased to 10 mg daily and an empiric regimen of intravenous amikacin (500mg IV every 12 hours), intravenous cefoxitin (2gm IV every 6 hours), and oral clarithromycin (500mg every 12 hours) was initiated. The patient initially did well and was discharged to home. He continued to do well as an outpatient, with decreased sputum production and without recurrence of fever. On day 15 of outpatient treatment however, the patient developed acute right- sided chest discomfort, and was again admitted to hospital; this time with a right-sided pneumothorax. A right-sided chest tube was inserted and the small amount of pleural fluid present was sent for analysis. The fluid proved to be exudative with a neutrophilic and monocytic predominance. Neither gram stain nor fluorochrome stain of the fluid revealed microorganisms;

Authors' Affiliation:
Department of Internal Medicine, Tripler Army Medical Center, Honolulu, HI 96859 (J.E.T., C.R.T., B.T.G., S.L.F.)

The opinions or assertions contained herein are the private views of the authors, and are not to be construed as official or as reflecting the views of the Department of the Army or the Department of Defense.

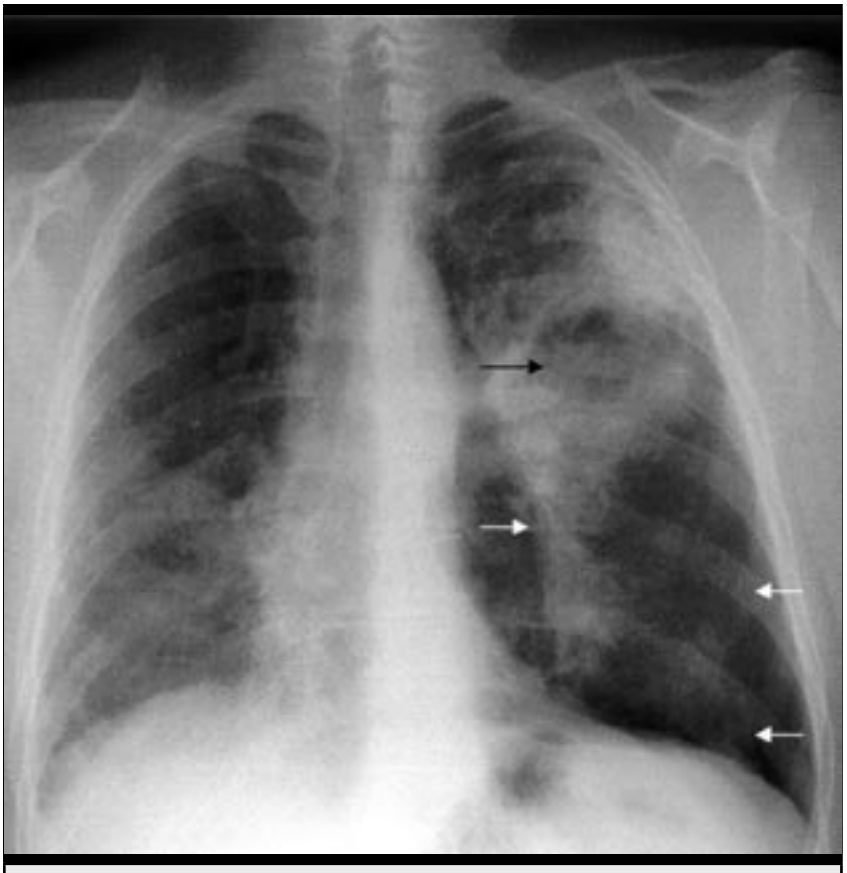

Figure 1b.— is the CXR from admission, 19 months from time of baseline CXR. It shows large opacified areas within the left upper lobe (black arrow), left perihilar area, and right lower lobe consistent with the patient's multilobar NTM pneumonia. The extensive left-sided pneumothorax is highlighted with white arrows.

however, *M. abscessus* was recovered from culture. Serologic studies obtained for *Mycoplasma pneumoniae*, *Coccidioides immitis*, *Cryptococcus neoformans*, and human immunodeficiency virus were all negative.

The patient continued to have a significant supplemental oxygen requirement despite an appropriately placed chest tube. Chest CT revealed parenchymal consolidation in multiple lobes and progression of interstitial fibrosis as compared with CT studies from the prior admission. Bronchoscopy, with right lower lobe transbronchial biopsy, was performed. The biopsy specimen demonstrated benign bronchial and alveolar lung tissue with numerous pigment-laden alveolar macrophages and focal areas suspicious for interstitial septal fibrosis. No granulomatous inflammation was identified, and broncho-alveolar lavage revealed no *Pneumocystis carinii*, malignancy, or fungal organisms. Fluorochrome stain of the specimen did not reveal acid-fast bacteria, but cultures were positive again for *M. abscessus*.

The patient's respiratory status continued to decline despite supportive care and continuation of antibiotics. The prednisone regimen was empirically increased, prior to the return of culture results, as therapy for presumed progression of his interstitial lung disease. The patient ultimately expired, as a result of overwhelming pulmonary infection, 20 days after readmission to hospital. Autopsy was performed and fluorochrome stain revealed the presence of acid-fast bacilli in the setting of several severe, bilateral, necrotic, granulomatous, cavitary pulmonary lesions. The autopsy findings were also notable for the absence of other pathogenic microorganisms. To our knowledge, this is the first reported case of fatal pulmonary *Mycobacterium abscessus* infection in a patient using etanercept.

Discussion

Background

M. abscessus belongs to the group of nontuberculous mycobacteria (NTM), which is also known as the "rapid growers." They are ubiquitous organisms that are often found in natural and processed water sources as well as in sewage and dirt. Other "rapid growers" include *M. chelonae, M. fortuitum* and *M. peregrinum*. This group is characterized by its ability to grow rapidly (2 - 7 days) at temperatures ranging from 25 to 42 degrees Celsius, and its tendency for abscess formation, especially at injection sites or surgical wounds. This group is also known for its close association with pulmonary disease, especially in cases of decreased host resistance.[6]

Pathogenesis

Etanercept has been approved in the United States for use in patients with rheumatoid arthritis, and a number of cases of pulmonary and disseminated *M. tuberculosis* infections have been associated with its use. No case of pulmonary *M. abscessus* infection, however, has been previously reported in association with its use.[3,4,5] Etanercept is a recombinant TNF receptor fusion protein that also targets TNF-α. TNF-α is a pro-inflammatory cytokine that is primarily produced by activated monocytes and macrophages in response to various pathogenic stimuli including those antigens involved in the pathogenesis of rheumatoid arthritis. The central role that TNF-α plays in the immune response to mycobacterial infection and its pathogenesis has not been fully elucidated. The release of TNF-α in response to mycobacterial infection is, however, known to be important in several respects: 1) TNF-α is a requirement for the process of granuloma formation which serves to inhibit bacterial dissemination, 2) TNF-α increases the ability of macrophages to phagocytose and kill bacteria, 3) TNF-α induces apoptosis of presumably ineffective macrophages, thereby depriving the organisms of an intracellular sanctuary.[2]

Treatment

In general, prolonged antibiotic therapy is required to treat nontuberculous mycobacterial infections. Intrave-

nous therapy is preferred for serious illness or disseminated disease. Some experts recommend two to six weeks of initial intravenous treatment followed by a long course of oral antibiotics. Empiric treatment for *M. abscessus* should include an aminoglycoside (amikacin is considered to be the aminoglycoside of choice). Cefoxitin is considered by many to be the beta-lactam of choice for *M. abscessus*. The fluoroquinolones may also have activity against these microorganisms. The use of a single agent is always to be avoided as the eventual development of resistance of these rapid growers is to be anticipated. All initial isolates should be tested for antibiotic sensitivity to guide therapy because the sensitivity patterns between isolates can vary considerably. Sensitivity testing prior to or early during treatment provides greater certainty as regards the efficacy of an antibiotic regimen. Although no standard duration of therapy exists for the treatment of pulmonary *M. abscessus* infection, some experts recommend obtaining monthly sputum cultures and treating for at least one year after the last positive sputum result.[7]

Conclusions

M. abscessus is known to be ubiquitous in the environment and persons with underlying chronic lung disease appear to be at greater risk for developing pulmonary NTM infection. It is impossible to know in retrospect whether our patient had been infected / colonized with *M. abscessus* prior to the initiation of etanercept, and the patient had no travel or occupational history which may have placed him at additional risk. We can report, however, that prior to the initiation of etanercept, our patient was without any ongoing symptoms such as fevers, night sweats, or weight loss that may have been consistent with chronic pulmonary NTM infection. Although tuberculin skin testing and treatment of latent *M. tuberculosis* infection are recommended prior to the initiation of etanercept, no specific pre-treatment evaluation or prophylaxis is recommended (or indicated) in regard to *M. abscessus* or other pulmonary NTM infections.[8]

It is difficult in this case to establish an indisputable causal relationship between the initiation of the etanercept regimen and the adverse clinical outcome for two reasons: 1) the patient was exposed to an ongoing multi-drug, immuno-suppression regimen (including prednisone and leflunomide) prior to the addition of etanercept and 2) a significant amount of time had elapsed (approximately 450 days) between the initiation of the etanercept regimen and the onset of the patient's adverse symptoms [the median time to onset of adverse events was 236 days as recorded in the Food and Drug Administration Adverse Event Reporting System (FDAAERS)].[3] Nevertheless, this case identifies the development of diffuse pulmonary infection with *M. abscessus*, an organism better known for its tendency to cause focal granulomatous lung disease, in a patient using etanercept. Furthermore, this case arises in the setting of a number of previously reported cases of pulmonary and disseminated *M. tuberculosis* infections associated with the use of etanercept, and is thought to occur by a similar, if not identical, mechanism of action. This being stated, we implicate etanercept as the most likely permissive agent, based on its mechanism of action, for this case of fatal pulmonary *M. abscessus* infection.

We recommend that physicians exercise cautious clinical judgment when initiating etanercept therapy in persons with underlying lung disease, especially in communities in which mycobacterial organisms are highly prevalent. We also advise physicians to maintain a high level of vigilance for late onset granulomatous infection in persons using etanercept.

References

1. Bathon, J., Martin, R., Fleischmann, R., et al. A comparison of etanercept and methotrexate in patients with early rheumatoid arthritis, New England Journal of Medicine 2000;343:1586-1593
2. Gardam MA, Keystone EC, Menzies R, et al. Anti-tumor necrosis factor agents and tuberculosis risk: mechanisms of action and clinical management, The Lancet Infectious Diseases 2003;3:148-155
3. Wallis RS, Broder MS, Wong JY, et al. Granulomatous Infectious Diseases Associated with Tumor Necrosis Factor Antagonists, Clinical Infectious Diseases 2004;38:1261-1265
4. Wallis WJ, Burge DJ, Sabath D, et al. Tuberculosis reports with etanercept (Enbrel®) therapy, Arthritis and Rheumatism 2001;44(suppl):S78
5. Tuberculosis Associated with Blocking Agents Against Tumor Necrosis Factor-alpha – California, 2002-2003. Morbidity and Mortality Weekly Report, 2004;53:683-686
6. Microbiology & Public Health Available at http://www2.provlab.ab.ca/bugs/mycob/runyoniv.htm . Accessed August 15, 2004
7. Woeltje KF. Mycobacterium Chelonae Available at http://www.emedicine.com/med/topic1533.htm. Accessed August 15, 2004
8. Hamilton CD. Editorial: Tuberculosis in the Cytokine Era: What Rheumatologists Need to Know, Arthritis and Rheumatism 2003;48(8):2085-209

Sudden staff illness?
Planned vacation?
Excess workload?

We can provide relief. Our staff is carefully screened and trained to perform in the most demanding situations. We offer:

- Registered Nurses
- Medical Assistants
- Licensed Practical Nurses

Kahu Malama Nurses, Inc.
Short and Long Term Relief Staffing
Temporary and Permanent Placement
21 Years Experience in Hospital Staffing
Locally Owned and Managed by Nurses

Call: 951-0111 Neighbor Islands: **800-773-9021**

www.kahumalama.com
1357 Kapiolani Blvd., Suite 850

Severe Vitamin D Deficiency in Hawai'i: A Case Report

Michael Bornemann MD, FACP, FACE

Michael Bornemann MD, FACP, FACE

Abstract

Severe vitamin D deficiency would appear unlikely to occur in Hawai'i, which has abundant year-round sun exposure. This case report of a woman with no obvious risk factors for vitamin D deficiency who was found to have severe vitamin D deficiency and coexisting primary hyperparathyroidism should alert health care providers to be more aware of vitamin D deficiency in Hawai'i.

Adequate levels of vitamin D are necessary for healthy bone growth and integrity and to prevent rickets and ostemalacia. Presenting in childhood, rickets produces skeletal deformities; vitamin D deficiency in adults leads to bone pain and predisposes to osteomalacia and fractures. Sufficient vitamin D stores are maintained through foods fortified with vitamin D and vitamin D generated by ultraviolet rays from sun exposure synthesizing vitamin D precursors in the skin. Historically, vitamin D deficiency is likely to occur in malnourished populations and in those with limited sun exposure. Because of abundant sun exposure in Hawaii and widespread vitamin D enrichment of food, vitamin D deficiency would seem unlikely to develop in this setting. This report describes a 76-year-old woman with generalized weakness and lower extremity pain who was found to have severe vitamin D deficiency. Although secondary hyperparathyroidism would be anticipated in the setting of vitamin D deficiency and hypocalcemia, the finding of coexisting primary hyperparathyroidism (hypercalcemia and elevated parathyroid hormone [PTH] levels) in this patient was unexpected. This report will discuss the clinical features of vitamin D deficiency and the relationship between vitamin D deficiency and primary hyperparathyroidism.

Case Report

The patient is a 76-year-old woman, born in Hawaii, who experienced progressive weakness over a several week period resulting in an inability to arise from a chair on the day of admission. She was brought to the emergency room by her family and admitted with a diagnosis of pneumonia (based on leukocytosis and abnormal chest X-ray) and urinary tract infection. She responded well to antibiotics but within several days her complaint of bilateral leg pain and weakness dominated her clinical picture. She had been active and ambulatory until several weeks prior to her admission when the lower extremity pain and weakness limited her activities; she denied any falls or injuries. Her past medical history included hypertension, treated with nifedipine, and long standing tobacco use (1-2 packs per day). Physical examination was noteworthy for full dentures, generalized skin hyperpigmentation, and diffuse tenderness of lower extremities especially along the anterior tibial surface. Initial laboratory studies showed an elevated calcium (11.0 mg/dl); an intact PTH level was elevated as well (150 pg/dl; normal 6-40). (A review of her outpatient lab results showed serum calcium of 12.0 mg/dl five months prior to hospitalization.) A 24-hour urine showed calcium excretion of 127 mg and a creatinine clearance of 63 ml/min. A parathyroid scan revealed activity in the right upper anterior neck consistent with a parathyroid adenoma. Although she was presumed to have primary hyperparathyroidism, this did not seem to explain her lower extremity pain and weakness. Further investigation included X-rays of hips and lower extremities that did not show fractures, but a bone scan that showed multiple bilateral rib fractures and 25-hydroxyvitamin D level was very low(7 ng/ml; nl 15-60). She was started on vitamin D replacement therapy and underwent surgical resection of a right upper parathyroid adenoma. Intraoperative PTH levels were measured and fell from 122 ng/ml immediately preoperatively to 14 ng/ml five minutes after removal of the adenoma. Pathology report described a 2 cm parathyroid adenoma. Her calcium remained normal during the remainder of her hospital stay. Her lower extremity pain persisted despite a normal 25-hydroxyvitamin D level one month after starting therapy.

Discussion

Vitamin D is a fat-soluble vitamin that functions in many ways like a hormone. The majority of vitamin D stores are achieved through the sun's ultraviolet rays activating vitamin D precursors in the skin. Skin hyperpigmentation, sun blockers, and aging decrease the formation of vitamin D_3 that is formed through this process. Although very few foods contain vitamin D naturally, some foods (e.g., milk, some breakfast cere-

Author Affiliation:
Associate Professor of Medicine, University of Hawaii, John A. Burns School of Medicine, Honolulu, HI 96813

Correspondence to:
Michael Bornemann MD
1585 Kapiolani Blvd, #1500
Honolulu, HI 96814

als and some orange juices) are fortified with vitamin D. Oily fish such as salmon, mackerel and sardines are an excellent source of vitamin D as is cod liver oil. Vitamin D_3 subsequently undergoes hydroxylation to 25-hydroxyvitamin D in the liver. Measurement of serum levels of 25-hydroxyvitamin D is a reflection of body stores of vitamin D. In the kidney 25-hydroxyvitamin D undergoes 1-alpha hydroxylation, producing the most potent form of vitamin D (1, 25 dihydroxyvitamin D or calcitriol). The major action of calcitriol is to facilitate calcium absorption in the small intestine. Other actions include suppression of PTH and possible effects on cellular development and maturation.[1] Because of the ubiquity of vitamin D receptors, vitamin D may have far-reaching effects; cancer and diabetes have been inversely linked to vitamin D levels.[2,3]

Although vitamin D deficiency might be expected in an institutionalized population with little sun exposure or limited nutritional supplementation of vitamin D, studies have documented significant vitamin D deficiency in free living populations[4,5] with prevalence of vitamin D deficiency as high as 30 percent during winter months in Boston.[4] However, it was surprising to find severe vitamin D deficiency in this patient who was not home-bound or institutionalized, was adequately nourished, and who presumably had sufficient sun exposure year round. Normal ranges for 25-hydroxyvitamin D vary but there is general consensus that levels below 20 ng/ml represent deficient vitamin D stores and levels below 32 ng/ml are associated with compensatory increases in PTH secretion that may adversely affect bone. Plotnick characterizes patients with levels <8 ng/ml as severely vitamin D deficient; this would define this patient whose level was 7 ng/ml.[5] Known causes of vitamin D deficiency include anticonvulsants, alcohol, theophylline that all impair the hydroxylation of vitamin D in the liver, malabsoption syndromes, gastrectomy, and inflammatory bowel disease; none of these appear to contribute to this patient's low vitamin D levels. Although the cause for her vitamin D deficiency is not clear, her dark skin and age are factors known to contribute to low vitamin D levels.

Symptoms of vitamin D deficiency are often not recognized. The most common symptom in adults is generalized musculoskeletal pain and weakness. This nonspecific presentation may be misdiagnosed as fibromyalgia, chronic fatigue syndrome, depression, or systemic lupus erythematosis. Vitamin D levels may actually be low in SLE and fibromyalgia and may play a significant role in symptoms.[5] A recent study of patients presenting to an inner city primary care clinic in Minneapolis with complaints of nonspecific musculoskeletal pains revealed a 90 percent incidence of vitamin D deficiency. Many of these patients did not fit the anticipated stereotype of malnourished, elderly, institutionalized persons.[5] It would then seem appropriate to screen patients with undiagnosed generalized musculoskeletal pain and weakness (especially in lower extremities) for vitamin D deficiency. Although the patient's nonspecific leg pains persisted one month after starting vitamin D therapy, longer follow up may be needed to assess symptomatic relief in such patients. Other groups that would benefit from screening include patients suspected of secondary osteoporosis and those with history of gastrectomy, malabsorption, inflammatory bowel disease or chronically on anticonvulsants or theophyllin.

The absence of any known factors for vitamin D deficiency other than age and skin hyperpigmentation in this patient raises the larger question of vitamin D deficiency in Hawai'i. Although no population studies have been done assessing vitamin D status in Hawai'i, a study was recently done in south Florida (latitude 25.46 N) which has a similar latitude and year round sun exposure as Hawaii (latitude of O'ahu 21.30 N).[6] That study showed that in winter 38 percent of men and 40 percent of women had vitamin D levels less than 20 ng/dl. Mean values in winter were 25 ng/ml in men and 22 ng/ml in women; levels increased during summer to 31 ng/ml in men and to 25 ng/ml in women. The prevalence of vitamin D deficiency in southern latitude such as south Florida or Hawaii may be due to a number of factors. Residents may avoid mid-day sun exposure because of the heat. Dark skin and the use of sun screens also impair vitamin D activation and older individuals may have decreased sun exposure and nutritional lack of vitamin D supplements. Clearly, vitamin D deficiency in Hawaii should be considered in at-risk patients as well as those with osteoporosis or nonspecific rheumatic complaints.

Prevention of vitamin D deficiency requires maintaining adequate vitamin D stores. Sun exposure accounts for as much as 90 percent of daily vitamin D requirements but supplemental dietary sources of vitamin D are necessary for individuals avoiding sun exposure, using sun block or in hyper pigmented individuals as increased skin melanin diminishes cutaneous production of vitamin D. Recommendations for supplemental vitamin D are age-dependent: 200 IU/day for age less than 50, 400 IU/day for age 50-70, and 600 IU/day for those over 70.[7] For those with little or no sun exposure vitamin D intake may need to be 1,000 IU/day. Although 25-hydroxyvitamin D levels below 20 ng/ml are generally considered to represent vitamin D deficiency, maintaining levels of 30-50 ng/ml are preferred to prevent rises in PTH levels. Treatment of vitamin D deficiency to achieve these levels would appear to be simple replacement with vitamin D preparations. A recent study showed that potency of vitamin ergocalciferol (D_2) was significantly less than cholecalciferol (vitamin D_3).[8] Most vitamin D preparations contain cholecalciferol but GNC Calcimate and Centrum Silver contain ergocalciferol. Furthermore, some assays for measuring 25 hydroxyvitamin D may not detect ergocalciferol, confounding laboratory follow-up of patients treated with vitamin D_2.[9] Whatever vitamin D preparation and dose are used, monitoring vitamin D levels and serum calcium are important to detect over-replacement.

The coexistence of vitamin D deficiency and primary hyperparathyroidism in this patient raises questions regarding this relationship. In endstage renal disease vitamin D deficiency (due to low levels of 1,25 dihydroxyvitamin D) leads to compensatory increases in PTH that subsequently result in secondary hyperparathyroidism (i.e., hyperplasia involving all four parathyroid glands) which in turn may lead to tertiary hyperparathyroidism (i.e., parathyroid adenomas with autonomous secretion of PTH). Therefore, is it possible that longstanding deficiency of 25 hydroxyvitamin D in patients without renal disease could also result in a similar picture of secondary and tertiary hyperparathyroidism? The resolution of this patient's elevated PTH level after removal of an adenoma suggests that the hyperparathyroidism was secondary to the adenoma and not from hyperplasia. Therefore it would appear more likely that the patient had primary hyperparathyroidism that was likely exacerbated by vitamin D deficiency. Because 25 hydroxyvitamin D

*See **Vitamin D**, p. 20*

An Unusual Abdominal Tumor — Leiomyosarcoma of the Mesentery: A Case Report

Catherine J. Simonovich MS4, John M. Hardman MD, James J. Navin MD, Jennifer Jacobs MD, and Neil Fergusson MD (in memoriam)

Catherine J. Simonovich MS4

John M. Hardman MD

Jennifer Jacobs MD

Authors' Affiliations:
- Department of Pathology, John A. Burns School of Medicine, Honolulu, HI 96813 (C.J.S., J.M.H., J.J.N.)
- Straub Clinic and Hospital, Honolulu, HI 96813 (J.J.N., N.F.)
- Department of Surgery, John A. Burns School of Medicine, Honolulu, HI 96813 (J.J., N.F.)

Correspondence to:
John M. Hardman MD
Department of Pathology
Medical Education Building
John A. Burns School of Medicine
University of Hawaii at Manoa
651 Ilalo St.
Honolulu, HI 96813

Abstract

We report the case of an 82-year-old woman who presented with an ill-defined mass and tenderness in the right lower quadrant of the abdomen. On computerized tomography scan, she had an irregular large bosselated mass of the mesentery located medial to the cecum and associated with multiple loops of small intestine. Preoperative differential diagnoses included leiomyosarcoma, lymphoma and gastrointestinal stromal tumor. The mesenteric mass was resected and identified as a leiomyosarcoma. This patient's tumor is typical of a mesenteric leiomyosarcoma and recurred with hepatic metastases two years after its initial removal. Such tumors usually do not become symptomatic until late in the course of disease, often after distant metastases have occurred. Mesenteric leiomyosarcomas are rare and have a reported incidence of 1: 350,000.

Introduction

Clinical assessment of an abdominal mass would particularly include common abdominal cancers found in elderly women. According to the NCI SEER Program, abdominal cancers of the colon and rectum, ovary, uterus, pancreas or lymph nodes are among the ten most commonly reported cancers in women in the United States. Soft tissue tumors of the abdomen are much less common and include gastrointestinal stroma tumors, lymphomas, liposarcomas and leiomyosarcoma.[1] Only 10 mesenteric leiomyosarcomas have been reported to the Hawaii Tumor Registry since 1979.[2] Such tumors often remain asymptomatic until late in the course of disease when metastases to the liver, and lungs appear. We report the tenth case in Hawaii of a mesenteric leiomyosarcoma.

Case Report

An 82-year-old woman presented to her primary care physician with new onset constipation of two to three months' duration. She did not complain of anorexia, abdominal pain, nausea, vomiting, fever, chills, or significant weight loss, and she did not have blood, mucus or color changes in her stool. Her past surgical history included a total abdominal hysterectomy and bilateral salpingo-oophorectomy for benign disease. She had no personal or family history of cancer. On physical examination, a questionable fullness or mass that was tender to deep palpation was felt in the right lower quadrant of the abdomen. She had no guarding, rebound tenderness or ascites. There were no rectal masses. Her stool was guaiac negative.

Abdominal computerized tomography showed an irregular bosselated 7.8 cm diameter soft tissue mass in the right lower quadrant of the abdomen just medial to the cecum and closely associated multiple small bowel loops (Fig. 1). There was no pelvic adenopathy, no retroperitoneal adenopathy and no adenopathy of the root of the mesentery. At the time of surgery, the tumor itself was very superficial to the posterior abdominal wall and appeared to be arising from the mesentery of the proximal jejunum. It was nonmalignant in appearance, multilobulated and somewhat cystic. There were inflammatory adhesions of the mass to the appendix, cecum and terminal ileum. The tumor was removed by a wedge resection of the mesentery involving a 15 cm segment of jejunum, and the patient's appendix was also removed because the tip of the appendix was well adherent to the mass. After surgery, the patient's bowel movements returned to normal and she had an uneventful postoperative recovery. Because the tumor was completely resected and there was no evidence of metastatic disease, adjuvant chemotherapy or radiation therapy was not recommended because those treatments would not demonstrate benefit in terms of overall survival.

Two years later, she developed a large ventral hernia and returned to the care of her surgeon. Except for malaise, she had no symptoms (e.g., nausea, vomiting, weight loss, fever, or appetite changes). Her bowel movements remained normal, and she did not have nausea or vomiting. On physical exam, she had an easily reducible large ventral hernia but abdominal masses or scleral icterus were not found. The patient's alkaline phosphatase was elevated but her other liver enzymes were normal. On computerized tomography

of the abdomen, a mass of the caudate lobe of the liver was suspicious for metastatic disease. Surgery was thus performed for a ventral hernia repair and biopsy of the liver mass, with possible partial liver resection. Multiple small liver metastases were determined to be unresectable, and a biopsy of the liver mass revealed a metastasis from the original mesenteric leiomyosarcoma. The patient's postoperative recovery was again uneventful.

Pathologic Findings

A multinodular firm tumor measuring 11.0 x 7.5 x 6.0 cm was located in the mesentery between the appendix and small bowel but not arising from either one. The tumor was firm and rubbery and had a white cut surface. There was also a second 3.2 cm circumscribed, pink nodule that appeared similar to the large tumor. The tumor was sharply demarcated from the mesenteric adipose tissue. Microscopically the tumor consisted of spindled cells arranged in interlacing fascicles with elongated nuclei and nuclear atypia (Fig 2). The tumor had up to 12 mitotic figures, many abnormal, per high-powered field. The stroma was well-vascularized and in some areas fibrotic. The pink nodule was more vascular. The tumor cells were more plump and had more eosinophilic cytoplasm, and some cells had small vacuoles in the cytoplasm. The tumor cells stained positively for actin, vimentin and desmin and negatively for c-kit and CD34. The histological features combined with the immunohistochemical findings are diagnostic for a leiomyosarcoma arising in the mesentery.

Discussion

A palpable mass is the most common presenting sign of a mesenteric leiomyosarcoma.[2,3] Yannopoulos and Stout state "the mobility of the mesentery often permits a tumor to grow to a very large size before it causes any symptoms other than a palpable mass."[3] Obstructive symptoms, such as constipation, are generally late findings.[1] Abdominal pain is also often found due to mass effect within the peritoneum or to traction on the mesentery and is usually manifested as deep and poorly localized discomfort.[1] Metastases are mainly to the liver and lungs.[4]

Abdominal CT is used to focus the diagnosis of these masses because they are located outside the intestines. The differential diagnosis includes leiomyosarcoma and other mesenteric tumors such as gastrointestinal stromal tumor, liposarcoma and lymphoma.[1-4] A definitive diagnosis of a leiomyosarcoma can only be made by pathological study. Treatment strategies vary, but surgical excision with a wide margin of normal tissue is the most effective.[6] Arteriography may help define areas of compromised mesenteric arterial blood supply. Chemotherapeutic agents that have been given for recurrences and metastases include intra-abdominal cisplatin and intravenous ifosfamide, pirarubicin hydrochloride, hydroxyurea, etoposide and dacarbazine.[1,7]

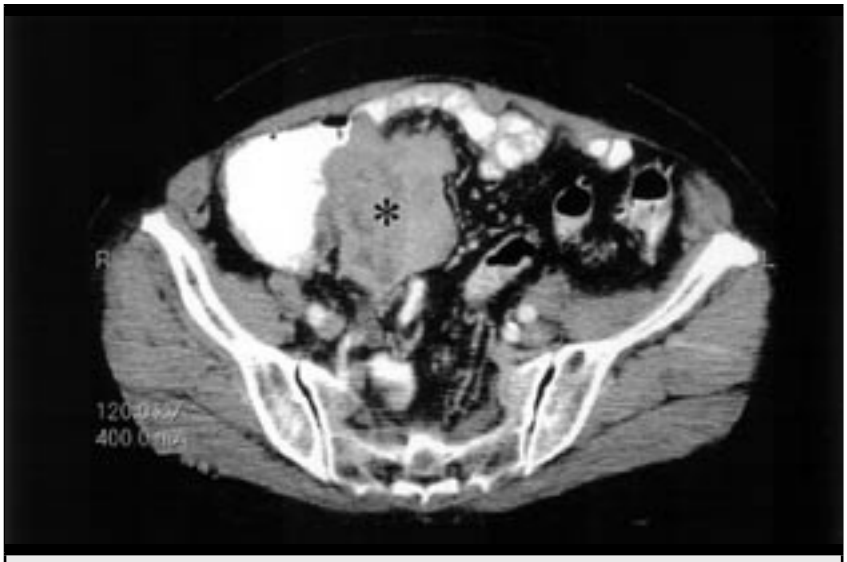

Figure 1.— CT Lower abdomen and pelvis. Large mesenteric tumor (*)



Figure 2A.— Leiomyosarcoma (Hematoxylin and cosin stain; original magnification X400)
Figure 2B.— Leiomyosarcoma (Actin positive stain; original magnification X400)

Tumor size is one of the major prognostic factors. The majority of these tumors are so large (>10 cm) at the time they are found that excision is often not feasible.[1] Other features of these tumors such as anatomic location, surgical treatment and histological variants have not been shown to have prognostic significance. Death is often caused by metastasis to the liver and lungs. The overall 5-year survival rate for this tumor is 20-30 percent.[5]

Leiomyosarcoma of the mesentery is a rare extra-intestinal sarcoma that is likely derived from the smooth muscle of blood vessels of the mesentery.[4] Tumor suppressor genes and related molecules in leiomyosarcoma affect the Rb-cyclin D pathways in about 90 percent of cases and p53 pathways in about

16.6 percent of cases.[8] Tumors of the mesentery range in incidence from 1/200,000-1/350,000, and about 2/3 of the cases are mesenchymomas (a mixed sarcoma containing leiomyosarcoma and liposarcoma).[1] Intraabdominal leiomyosarcomas, arising in the retroperitoneum, mesentery or omentum, account for 40-45 percent of soft tissue leiomyosarcomas.[5]

A clinicopathologic analysis of 44 cases of leiomyosarcoma of the mesentery and retroperitoneum showed that patients with this condition typically range in age from 30 to 96 years, with a median age of 59 years.[4] Sixty-one percent of the patients were women and thirty-nine percent were men. One report identified an omental leiomyosarcoma in a 15-year-old girl.[7] Ethnic predispositions for this tumor are not known; however, cases have been described in many nations throughout the world, including the United States, Italy, Japan, China and France. The Hawai'i Tumor Registry has ten cases of leiomyosarcoma of the mesentery reported since 1979, including this case. In this series, the average age at diagnosis was 63 years, ranging from 38 to 88 years. Half of the patients were men and half were women. Five patients were Japanese, two Filipino, and one each Chinese, Korean and Hawaiian.[2]

Acknowledgments

Mark Goodman kindly provided information on cases of leiomyosarcoma of the mesentery in Hawaii from the Hawaii Tumor Registry.

References

1. Seymour, NE. Mesenteric Tumors. Emedicine. December 13, 2002 Available: http://www.emedicine.com/med/topic2728.htm.
2. Goodman, M. Results of Query of Hawaii Tumor Registry Database for Leiomyosarcoma of the Mesentery. 2005. Hawaii Tumor Registry, Cancer Research Center, Hawaii, Honolulu.
3. Yannopoulos K, Stout AP. Primary Solid Tumors of the Mesentery. Cancer 1963; 16(7):914-927.
4. Hashimoto H, Tsuneyoshi M, Enjoji, M. Malignant Smooth Muscle Tumors of the Retroperitoneum and Mesentery: A Clinicopathologic Analysis of 44 Cases. J Surg Oncol 1985;28:177-186.
5. Fukunaga M. Neuron-Specific Enolase-Producing Leiomyosarcoma of the Mesentery. Acta Pathol Microbiol et Immunol Scandinavica 2004;112:105-8.
6. Takabashi T, Kuwao S, Yanagihara M, et al. A Primary Solid Tumor of the Lesser Omentum With Immunohistochemical Features of Gastrointestinal Stromal Tumors. Amer J Gastroenterol 1998;93(11):2269-2273.
7. Niwa K, Hashimoto M, Hirano S, Mori H, and Tamaya T. Primary Leiomyosarcoma Arising From the Greater Omentum in a 15-Year-Old Girl. Gynecol Oncol 1999;74:308-310.
8. Dei Tos AP, Maestro R., Doglioni C, et al. Tumor Suppressor Genes and Related Molecules in Leiomyosarcoma. Amer J Pathol 1996; 148(4):1037-1045.

Are you HIPAA Security Compliant?

Go from "Overwhelmed" to "Ready" Quickly, easily and affordably.

Call us for an initial consultation at no charge.

(808) 395-4949

Automation Management Consultants LLC

LeRoy Brown, CISSP*, CHSS*, MCSE*

Serving Hawaii Since 1987

*Certified Information Security Specialist Professional (CISSP)
*Certified HIPAA Security Specialist (CHSS)
*Microsoft Certified Systems Engineer (MCSE)

***Vitamin D**, from p. 17*

exerts a negative feedback on PTH secretion, vitamin D deficiency may stimulate the growth of parathyroid adenomas. Indeed, an inverse relationship has been seen between vitamin D deficiency and the weight of parathyroid adenomas.[10] Further evidence supporting the adverse of effect of vitamin D deficiency on primary hyperparathyroidism is a study by Bandeira showing increased severity of disease with vitamin D deficiency.[11] Treatment of vitamin D deficiency has occasionally resulted in hypercalcemia and an unmasking of primary hyperthyroidism.[12] However, a recent prospective study of vitamin D replacement in vitamin D deficient patients with coexisting mild primary hyperparathyroidism did not exacerbate hypercalcemia during an observation period of one year.[13] Therefore, the treatment of vitamin D deficiency would appear safe in most cases; the emergence of hypercalcemia in this setting would suggest either vitamin D intoxication (high serum levels of 25 hydroxyvitamin D and suppressed PTH levels) or the unmasking of primary hyperparathyroidism (elevated PTH levels).

In summary, severe vitamin D deficiency exists in Hawai'i and high risk individuals should be screened. Additionally, patients with vague, unexplained lower extremity pain and patients with mild primary hyperparathyroidism may also benefit from vitamin D screening.

References

1. Clemens TL, O'Riordan JLH. Vitamin D. In Becker, KL, ed. Principles and Practice of Endocrinology and Metabolism, 2nd ed. Philadelphia, PA: J.B. Lippincott Company; 1995: 488.
2. Scragg R, Sowers MF, Bell C. Serum 25-hydroxyvitamin D, diabetes, and ethnicity in the third national health and nutrition examination survey. Diabetes Care. 2004,27:2813-2818.
3. Tangpricha V, Pearce EN, Chen TC, Holick MF. Vitamin D insufficiency among free-living healthy young adults. Am J Med. 2002,112:659-662.
4. Holick MF. Vitamin D: Importance in the prevention of cancers, type 1 diabetes, heart disease and osteoporosis. Am J Clin Nutr. 2004,79:362-371.
5. Plotnikoff GA, Quigley JM. Prevalence of severe hypovitaminosis D in patients with persistent, nonspecific musculoskeletal pain. Mayo Clin Proc. 2003,78:1463-1470.
6. Levis S, Gomez A, Jimenez C, et. al. Vitamin D deficiency and seasonal variation in an adult south Florida population. J Clin Endocrinol Metab. 2005,90:1557-1562.
7. Holick MF. Vitamin D deficiency: what a pain it is. Mayo Clin Proc. 2003,78:1457-1459.
8. Armas LAG, Hollis BW, Heaney RP. Vitamin D2 is much less effective than vitamin D3 in humans. J Clin Endocrinol Metab. 2004,89:5387-5391.
9. Hollis BW. The determination of circulating 25-hydroxyvitamin D: no easy task. J Clin Endocrinol Metab. 2004,89:3149-3151.
10. Sudhaker Rao D, Honasoge M, Divine G, et. al. Effect of vitamin D nutrition on parathyroid adenoma weight: pathogenetic and clinical implications. J Clin Endocrinol Metab, 2000.85,1054-1058.
11. Bandeira, F, Caldas G, Freese E, et. al. Relationship between serum vitamin D status and clinical manifestations of primary hyperparathyroidism. Endocr Pract. 2002,;8:266-270.
12. Taylor AV, Wise PH. Treatment of vitamin D deficient osteomalacia may unmask autonomous hyperparathyroidism. Postgrad Med J. 1997,73:813-815.
13. Grey A, Lucas J, Horne A, et.al. Vitamin D repletion in patient with primary hyperparathyroidism and coexistent vitamin D insufficiency. J Clin Endocrinol Metab. 2005,90:2122-2126.

Until there's a cure there's the American Diabetes Association.

HAWAI'I MEDICAL JOURNAL

Case Report: A 17-year-old Female with Headache and Fever

John Misailidis MD, Internal Medicine/Pediatrics Resident
Anna Dodd MD, Internal Medicine/Pediatrics Resident
Douglas Kwock MD, Pediatric Infectious Disease
Dominic Chow MD, Associate Professor

UH John A. Burns School of Medicine

A 17-year-old female with no significant past medical history was admitted for fever associated with headache and vomiting. The patient was in her usual state of good health until six days prior to admission, when she developed a tactile fever. The patient became fatigued and anorectic. Two days prior to admission, she developed a generalized headache associated with photophobia. She was seen at her local emergency department (ED) where she was administered intravenous fluids. A complete blood count was completed (Table 1). She was diagnosed with a viral illness and discharged home.

Over the next two days, the patient additionally developed a sore throat and generalized abdominal pain. She returned to her local ED where she was noted to have erythematous, enlarged tonsils. She felt nauseous, and vomited clear fluid. Blood tests were again completed, including a liver function profile. A rapid streptococcal antigen test was positive, and the patient was administered amoxicillin. The patient was then transferred to the children's hospital for further evaluation and treatment.

The patient continued to complain of a headache but denied neck stiffness or photophobia. She felt warm and experienced chills. She was nauseous, and vomited clear fluid on the morning of admission. Upon review, the patient denied any recent sick contacts. She denied any alcohol or drug use. She was not sexually active, and had no history of sexually transmitted diseases. Nine days prior to admission, the patient went swimming in the ocean, into which freshwater tributaries drain. She resided near an abandoned farmhouse, and states she frequently saw rats on the premises. The patient stated that one week prior to admission, a rat "ran into my [the patient's] leg" as she exited her home. The rodent did not bite her.

On physical exam, the patient had a temperature of 100.2^0 F, pulse rate of 106 beats/minute, respiratory rate of 20 breaths/minute, and a blood pressure of 105/45 mm Hg. The patient appeared uncomfortable and tired. Her sclera were injected. No photophobia was noted. Her posterior oropharynx was mildly erythematous, without tonsillar enlargement or exudates. She had shotty lymphadenopathy in the posterior cervical region. There was no neck stiffness. Abdominal exam revealed generalized abdominal tenderness with the liver edge 3 cm below the right costal margin, and the spleen tip noted 2 cm below the left costal margin. A chest X-ray was normal. A computed tomography (CT) scan was completed, which showed moderate liver and splenic enlargement. A group A streptococcal throat culture, an anti-nuclear antibody titer, and a hepatitis panel were obtained. Epstein-Barr virus, cytomegalovirus leptospirosis, rickettsia typhi and dengue fever titers were also drawn (Table 2). Treatment with doxycycline and ceftriaxone was initiated.

Table 1.— Laboratory Test Results

Variable	2 Days Prior to Admission	Day of Admission	Fifth Hospital Day
White cells (109/L)	5.8	6.4	11.6
Hemoglobin (mg/dL)	13.6	10.9	11.1
Hematocrit (%)	41.5	32.7	33.4
Differential count (%)			
Neutrophils	87	34	57
Bands		45	
Lymphocytes	11	19	31
Monocytes	1	1	8
Eosinophils	0	1	4
Platelets (109/L)	146	73	334
Reticulocyte count (%)		0.7	
Sodium (mmol/L)	136	132	138
CO2 (mmol/L)	25	23	3.8
BUN (mg/dL)	10	6	
Creatinine (mg/dL)	1.0	0.6	
Alkaline Phosphatase (U/L)		241	217
LDH (U/L)		436	
AST (U/L)		200	114
ALT (U/L)		241	115
Albumin (g/dL)		2.9	3.1
Bilirubin, Total (mg/dL)		1.0	0.5
Ammonia (mmol/L)		24	
Protime (sec)		16.2	14.7
Protime (1:1 mix) (sec)		14.2	
PTT (sec)		45	
D-dimer (mg/mL)		2.0 – 3.9	
FDP (mg/mL)		5 - <20	

On the second hospital day, the patient developed a palpable, pinpoint, erythematous rash that started on the trunk and abdomen,

Table 2.— Serolgies		
Variable	Result	Range
R. Typhi IFA		
IgM	1:512	Negative: < 1:64
IgG	1:512	Negative: < 1:64
Dengue Fever IFA		
IgM	7	Negative: < 9
IgG		Negative: < 9
EBV Antibody		
IgM	0.50	Negative: 0.00 to 0.99 IV
IgG	6.51	Negative: 0.00 to 0.99 IV
Cytomegalovirus		
IgM	< 8	Negative: < 8
IgG	128	Negative: < 16
ANA titer	160	Negative: < 40
Reflex ANA panel	negative	
Hepatitis A, B and C panels	nonreactive	
Group A strep throat culture	no growth	

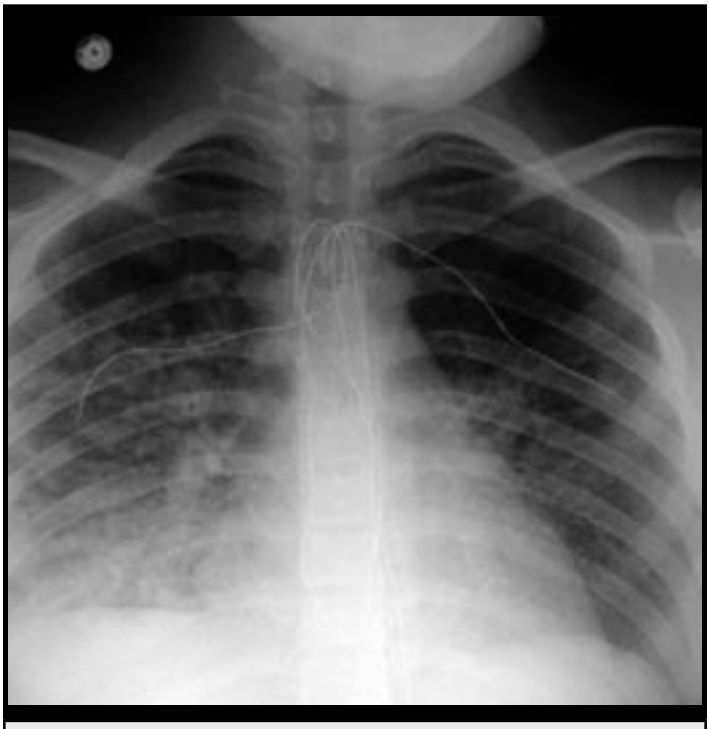

Figure 1.— Chest radiograph of patient.

and spread to her cheeks and nasal bridge. She became hypotensive, and required intravenous fluids to stabilize her blood pressure. Clindamycin was added to her antibiotic regimen.

On the third hospital day, the patient developed mild respiratory distress, with an oxygen saturation of 88% on room air. She was administered three liters of oxygen by nasal cannula. A repeat chest radiograph (Figure 1) demonstrated pulmonary infiltrates in the right lung fields, as well as a small infiltrate in the left perihilar region. Over the next 2 days, the patient improved dramatically. Her symptoms resolved, blood pressure remained stable, and she no longer required oxygen. Her laboratory tests, including platelet count, electrolytes, coagulation studies and liver function tests also improved. A repeat chest radiograph was normal. On the fifth hospital day, she was discharged on oral doxycyline. A few days after discharge, the indirect fluorescent antibody test for rickettsia typhi was reported as positive, with IgM and IgG levels of 1:512 each.

Discussion

Murine typhus is a flea-borne disease caused by *Rickettsia typhi* (*R. typhi*), an obligate intracellular, rod- to coccoid-shaped gram-negative bacteria. It is transmitted by arthropods, and primarily by the rat flea, Xenopsylla cheopis. Additional vectors, such as the cat flea, Ctenocephalides felis, have recently been implicated in urban and suburban outbreaks of murine typhus.[1,2] Most cases are associated with rat infestations, though recent studies in California suggest that the classic rat-flea cycle of rickettsia typhi has been replaced by feral cats, skunks, opposums, mice and their fleas.[1] A case of murine typhus on the island of Maui was associated with a kitten heavily infested with fleas.[3]

The *R. typhi* organisms enter the small bowel epithelial lining of the flea during a bloodmeal.[4] Most fleas defecate while biting; the feces of infected fleas contain the rickettsial organism. Infection occurs when the rickettsiae enter the body through the bite wound or from a person scratching the bite area. Though uncommon, it is possible to get murine typhus by inhaling contaminated, dried flea feces.[5] Dust in rodent harborages can contain flea feces for years after the rodents have gone.[3]

Epidemiology

Murine typhus has worldwide distribution, including southeast Asia, the Americas, Africa, and Mediterranean countries.[2,4,6,7] It has recently been reported in non-endemic areas such as rural New Zealand and Australia,[8,9] and re-emergence of the disease appears to be occurring in urban areas of Japan and Singapore.[10,11,12]

Murine typhus was first diagnosed in Hawai'i in 1933. Prior to and during World War II, it was widespread; 42,000 cases were reported in the United States from 1931 to 1946.[13] The incidence of typhus in Hawai'i peaked in 1944 when 186 cases were reported.[3] Cases were controlled in the 1940's and 1950's by dusting Dichloro-Diphenyl-Trichloroethane (DDT) into rodent burrows. The number of cases declined in the United States by the 1980's to approximately 100 cases per year. Currently, the highest rates of murine typhus in the country occur in Texas, Southern California and Hawai'i.[2,3,14] The number of cases in Hawai'i has risen dramatically over the past few years. From 1994 to 1998, a total of 33 cases were reported in Hawai'i; in 2002, 47 cases were reported, the largest number recorded annually since 1947.[13] This trend has continued, as 38 cases were reported in 2003.[15] Furthermore, it is thought that due to its generalized findings at presentation, murine typhus is often underreported or unrecognized.[2,16] Thus, the true incidence in Hawai'i, as well as the rest of the United States, may be considerably higher.

The macroenvironment of murine typhus consists of a hot, dry climate with little rainfall. In temperate climates, most cases occur in late spring and summer due to the increase in fleas during this period.[2,13] In Hawai'i, most cases of murine typhus occur from July through October, though cases do occur year-round.[13] Most cases occur on the areas of Maui where there is little rainfall, while few cases are noted in areas of heavy rainfall, such as Hilo.[3]

Pathology

R. typhi has a tropism for endothelial cells that line blood vessels. Thus, the primary pathological lesion is an inflammatory vasculitis, characterized by perivascular inflammation of lymphocytes, macrophages, plasma and mast cells.[17] This vasculitis may cause organ damage, including damage to the liver, lungs, kidneys, and central nervous system.[18] For example, in the liver, biopsies showing destructive portal tract and sinusoidal infiltrates have been noted.[19] Rickettsial infection of the pulmonary microvasculature may lead to interstitial pneumonia, diffuse alveolar damage, and increased vascular permeability in the lungs.[20] Pulmonary infiltrates represent a pneumonitis caused by small vessel vasculitis.[16] A perivascular interstitial nephritis caused by murine typhus has been reported.[16,21] *R. typhi* organisms can affect small cerebral blood vessels, creating nodules of glial cells and mononuclear cells surrounding grey matter capillaries.[22] A systemic inflammatory response results in the leakage and intravascular depletion of volume, albumin and electrolytes. Consumption of platelets may occur at sites of vascular inflammation.[18]

Patient History

A patient's history may point toward a diagnosis of murine typhus. Rodent exposure is an obvious red flag. The possible role of non-rodent disease reservoirs in transmitting typhus (cats, mice) must also be considered. A history of a fleabite is equally important, but the patient-reported history of fleabite or exposure to flea-bearing animals is also low.[2,11,16] Murine typhus typically occurs near seaports or in rural areas, though infection in urban centers has been reported in increasing frequency.[12,16] The abrupt nature of the illness may be another clue to diagnosis. A fever of unknown origin, especially in endemic areas, should alert the physician to murine typhus as a possible cause.[23] In one endemic area, 75 percent of unexplained fevers were determined to be caused by murine typhus.[6]

Clinical Features

Clinical and laboratory findings of murine typhus are fairly similar in adult and pediatric patients, though some differences do exist.[2] The disease typically has an incubation period from 8 to 16 days, and the onset of illness is abrupt in most patients.[16] Fever, headache, chills and myalgias are usually prominent early. Non-specific gastrointestinal symptoms (nausea, vomiting, abdominal pain, diarrhea) frequently occur, and are more common in children.[16,24] Murine typhus may cause symptoms that mimic an acute abdomen, thus prompting surgical intervention.[25]

The classic triad of murine typhus is fever, headache and rash. This triad, however, is infrequently seen; in one series, it occurred in only 49 percent of patients.[24] Fever and headache are common symptoms, occurring in 84-100 percent and 76-88 percent of patients, respectively.[2,7,12,16,24] Fever was less often observed in children, occurring in less than 25 percent of patients.[18]

When rash is present with fever and headache, the diagnosis of murine typhus is made more frequently.[24] The rash is typically macular or maculopapular. It is classically described as starting on the trunk and spreading peripherally, generally spares the palms and soles. Rash typically presents after six days of illness, and persists for a mean of five days.[2] Furthermore, it develops an average of two days after initial physician contact, thus limiting its initial diagnostic usefulness. Fifty-four to 80 percent of patients develop a rash during some point in the illness, though case series from Singapore and Thailand noted rash to be present in only 4-20 percent of patients, respectively.[3,7,11,16,24] Rash may be more difficult to discern in darker-skinned individuals.[25]

Table 3.— Clinical Factors Associated with Increased Disease Severity[16]

older age
delayed diagnosis
thrombocytopenia
hypoalbuminemia
coagulopathy
cardiac arrhythmias
hepatic dysfunction
renal dysfunction
central nervous system abnormalities
previous therapy with sulfa drugs
hemolysis (i.e. G6PD deficiency)

The occurrence of hepatomegaly (23-25 percent) is common, as well as splenomegaly (5-22 percent).[7,16,19] Jaundice has been noted as well, especially in patients with underlying glucose-6-phosphate dehydrogenase (G6PD) deficiency.[19] Palpable cervical lymphadenopathy may be present.[23] Cough and dyspnea may be present, and appear to be more common features in children.[3] Chest radiography may occasionally demonstrate diffuse pulmonary infiltrates, as in our patient. As noted, these infiltrates may represent a small-vessel vasculitis within the lungs.[3,7,26] Pulmonary edema and respiratory failure has been reported in *R. typhi* infection.[18] Cardiac complications are rare, though a case of murine typhus endocarditis has been reported.[27] Neurological manifestations of murine typhus are rare, especially in children.[24] Reports of murine typhus meningitis and encephalitis have emerged.[25,28] Patients may rarely present with mental confusion, seizures, ataxia or hallucinations.[16] A case report of a patient with peripheral facial palsy and meningitis has been associated with murine typhus.[29] Renal failure may result from decreased renal perfusion. In rare cases, patients may become hypotensive or develop multiorgan failure.[3,26]

Laboratory Features

The majority of patients will have an elevated erythrocyte sedimentation rate.[2] Patients typically present with a normal leukocyte count or leukopenia with an associated left shift.[18] Leukopenia is an especially suggestive finding, seen in up to 40 percent of patients.[2] Leukocytosis is uncommonly seen, especially in children.[26] Thrombocytopenia is common, seen in half of all patients, with the nadir occurring eight days after the onset of illness.[16] Anemia is not commonly seen, though patients with concomitant G6PD deficiency may develop severe hemolysis.[19] Mild to moderate elevations of the prothrombin time may occur, usually without clinical effect.[16] An elevated lactate dehydrogenase (LDH) is common, with a mean elevation of 320 U/L in one study.[7] Two patients during an outbreak on the island of Kaua'i had LDH levels of 2382 and 1247 U/L, respectively.[3]

Elevation of transaminases is extremely common, seen in up to 90 percent of patients. Aspartate aminotransferase (AST) and alanine aminotransferase (ALT) levels usually rise two times the upper limit of normal (mean of 103 and 99 U/L, respectively); however, levels may rise up to five times the upper limit of normal in approximately 25 percent of patients.[19] Overt liver failure is rare unless associated

with an underlying liver pathology, such as chronic hepatitis or cirrhosis.[19] Serum albumin and protein levels are frequently low, due to vasculitis-induced extravasation of protein.[24] Renal failure generally presents as a pre-renal azotemia.[16] Hyponatremia is seen in up to 70 percent of patients; the mechanism for this abnormality is unknown.[7]

Diagnosis

The diagnosis of murine typhus is usually clinically based. The diagnosis is most commonly confirmed serologically with an indirect fluorescent antibody test (IFA); alternatively latex agglutination, complement fixation, or enzyme immunoassay may be used.[30] The Weil-Felix agglutination test is non-specific, insensitive, and no longer recommended as a screening or diagnostic test.[18] The diagnosis is established by a fourfold rise in serum antibody titer to typhus group antigen between acute and convalescent serum specimens taken greater than or equal to two weeks apart, with a minimum convalescent titer of greater than or equal to 1:64.[3,31] A single high antibody titer of 128 or more to typhus group antigen may also be indicative of disease.[2,16] Diagnostic titers are present in approximately 50 percent of patients within one week and almost all patients within 15 days after the onset of illness.[32]

Differential Diagnosis

The differential diagnosis for murine typhus is broad. It includes, though not exclusively, the following diagnoses: viral exanthem, influenza, Epstein-Barr infection, meningococcemia, dengue fever, typhoid fever, gram negative-septicemia, Kawasaki disease, leptospirosis, toxic shock syndrome, Lyme disease, acute hepatitis, pneumonitis, meningitis or encephalitis.[18,25] Reports of patients with murine typhus co-infected with leptospirosis have been documented.[3] Rocky mountain spotted fever and ehrlichiosis should be considered only in travelers returning from areas endemic with these illnesses. Because of the severe headache and fever associated with murine typhus, meningitis should be an important consideration in the differential diagnosis. Murine typhus should also be considered in fever of unknown origin, as well as in tourists returning from endemic regions and presenting with a febrile illness.[6,11,33]

Treatment

Murine typhus generally has a benign clinical course. Generally, complete recovery occurs even without antibiotic treatment.[2] However, as noted, complications can occur, and antimicrobial therapy should not be withheld pending serological results.[16] Appropriate antibiotic therapy shortens the duration of fever by approximately one week and may prevent life-threatening complications.[2]

A tetracycline or chloramphenicol are the only effective antibiotics, and hasten the rate of recovery. A few case reports have shown that fluoroquinolones may be effective, but this class of antibiotics is not currently recommended as treatment.[34] The drug of choice is doxycycline in nonpregnant adults and children. Chloramphenicol is the drug of choice in pregnant women and those in whom life-threatening reactions to doxycycline is reported. Doxycycline in adults and children greater than or equal to 45 kg is given as 100 mg twice daily. Children less than 45 kg should receive 2.2 mg/kg of doxycycline twice daily. Tetracyclines can cause dental staining when administered to children, but the available data suggests this does not occur with one course.[31] The optimal duration of therapy has not been established. It is recommended that treatment with doxycycline be continued until the patient is afebrile greater than 72 hours and clinical improvement is documented (usually 7-10 days).[13,31]

Outcome and Prevention

Murine typhus is usually associated with a favorable outcome, with or without treatment. However, complications do occur. In one study, 10 percent of patients required admission to the intensive care unit. The mortality rate can reach approximately 4 percent.[24] The severity of illness has been associated with several factors, as listed in table 3.

Prevention is directed towards rodent and flea eradication programs. The rat flea must be controlled first with insecticides – otherwise the flea will seek alternative hosts. The department of health must be notified as soon as possible to monitor the rodent/flea population in the case area. No treatment is indicated for individuals exposed to the disease.[31] Recovery from murine typhus infection confers lifelong immunity to reinfection.[32]

References

1. Sorvillo, FJ, Gondo B, Emmons, R, et al. A suburban focus of endemic typhus in Los Angeles county: association with seropositive domestic cats and opposums. Am J Trop Med Hyg 1993;48:269-73.
2. Fergie JE, Purcell K, Wanat D. Murine typhus in south Texas children. Pediatr Infect Dis J 2000;19:535-38.
3. Manea SJ, Sasaki, DM, Ikeda, JK, et al. Clinical and epidemiological observations regarding the 1998 Kauai murine typhus outbreak. Hawai'i Med J 2001;60:7-11.
4. Azad AF, Radulovic S, Higgins JA, et al. Flea-borne rickettsiosis: ecological considerations. Emerg Infect Diseases 1997;3:319-27.
5. Murine Typhus. Retrieved December 20, 2004, from the Texas Department of State Health Services website at http://www.tdh.state.tx.us/zoonosis/diseases/typhus/typhus.asp
6. Duffy P, Le Guillouzic H, Gass R, et al. Murine typhus indentified as a major cause of febrile illness in a camp for displaced Khmers in Thailand. Am J Trop Med Hyg 1990;43(5):520-526.
7. Gikas A, Doukakis S, Pediaditis, J, et al. Murine typhus in Greece: epidemiological, clinical and therapeutic data from 83 cases. Trans R Soc Trop Med Hyg 2002;96(3):250-3.
8. Roberts S, Hill P, Croxson M, et al. The evidence for Rickettsial disease arising in New Zealand. New Zeal Med J 2001;114(1138):372-4.
9. O'Connor LF. A Cluster of murine typhus cases in Western Australia. Med J Aust 1996;165:24-26.
10. Sakaguchi S, Sato, I, Muguruma, H, et al. Letters: Reemerging Murine Typhus, Japan. Emerg Infect Diseases 2004;10(5):964-5.
11. Ong AKY, Tambyah PA, Ool S, et al. Endemic typhus in Singapore – A re-emerging infectious disease? Singapore Med J 2001;42(12):549-52.
12. Chen MIC, Chua KT, Lee CC, et al. Epidemiological, clinical and laboratory characteristics of 19 serologically confirmed Rickettsial disease in Singapore. Singapore Med J 2001;42(12):553-58.
13. CDC. Murine Typhus – Hawai'i, 2002. MMWR 2003;52(50):1224-26.
14. CDC. Summary of Notifiable Diseases, United States. MMWR 1991;40(53):34.
15. Associated Press. 15 murine typhus cases in Hawai'i so far. Retrieved December 28, 2004 from the Honolulu Advertiser.com at http://the.honoluluadvertiser.com/article/2004/Jul/12/ln/ln11a.html
16. Dumler SJ, Taylor JP, Walker DH. Clinical and laboratory features of murine typhus in South Texas, 1980 through 1987. JAMA 1991;266:1365-70.
17. Sexton, DJ. Murine Typhus. In: UpToDate, Rose BD (Ed), UpToDate, Wellesley, MA, 2004.
18. Dumler JS. Murine typhus. Semin Pediatr Infect Dis 1995; 5(2)137-42.
19. Silpapojakul K, Mitarnun W, Ovartlarnporn B. Liver involvement in murine typhus. Q J Med 1996; 80(8):623-29.
20. Walker DH, Parks FM, Betz TG, et al. Histopathology and immunohistologic demonstration of the distribution of Rickettsia typhii in fatal murine typhus. Am J Clin Path 1998;91:720-4.
21. Shaked Y, Shpilberg O, Samra Y. Involvement of the kidneys in Mediterranean spotted fever and murine typhus. Q J Med 1994;87(2):103-7.
22. Galanakis E, Gikas A, Bitsouri M, et al. Rickettsia typhi infection presenting as subacute meningitis. J Child Neurol 2002;17(2):156-7.
23. Bitsori M, Galanakis E, Gikas A, et al. Rickettsia typhi infection in childhood. Acta Paediatr 2002;91(1):59-61.
24. Whiteford SF, Taylor JP, Dumler JS, et al. Clinical, laboratory, and epidemiologic features of murine typhus in 97 Texas children. Arch Pediat Adol Med 2001;155(3):396-400.
25. Silpapojakul K, Chayakul P, Krisanapan S, et al. Murine typhus in Thailand: clinical features, diagnosis and treatment. Q J Med 1993;86:43-7.
26. Bernabeu-Wittel M, Pachon J, Alarcon A, et al. Murine typhus as a common cause of fever of intermediate duration: a 17-year study in the south of Spain. Arch Intern Med 1999;159(8):872-6.
27. Buchs AE, Zimlichman R, Sikuler E, et al. Murine typhus endocarditis. South Med J 1992;85(7):751-3.
28. Silpapojakul K, Ukkachoke C, Krisanapan S, et al. Rickettsial meningitis and encephalitis. Arch Intern Med 1991;151(9):1753-7.
29. Vander T, Medvedovsky M, Valdman S, et al. Facial paralysis and meningitis caused by Rickettsia typhi infection. Scand J Infect Dis 2003;35:886-7.
30. Edwards M, Feigin R. Rickettsial Infections. In: Feigin and Cherry, eds. Textbook of Pediatric Infectious Disease. 5th ed. Vol. 2, Saunders Publishing, 2004:2505-06.
31. American Academy of Pediatrics. Endemic typhus. In: Pickering LK, ed. Red Book: 2003 Report of the Committee on Infectious Diseases. 26th ed. Elk Grove Village, IL: American Academy of Pediatrics; 2003: 668-69.
32. Dumler J, Walker D. Rickettsia typhi (murine typhus). In: Mandel, Douglas and Bennet, eds. Principles and Practice of Infectious Disease, 5th ed. Vol. 2. Churchill Livingstone, 2000:2053-55.
33. Van Der Kleij FGH, Gansevoort RT, Kreeftenberg HG, et al. Imported Rickettsioses: think murine typhus. J Intern Med 1998;243(2):177-9.
34. Eaton M, Cohen M, Shlim D, et al. Ciprofloxacin-treatment of typhus. JAMA 1989;262:772-3.

Department of Pediatrics at the John A. Burns School of Medicine (JABSOM) 2004-2005 Update

Raul C. Rudoy MD
John A. Burns School of Medicine
Professor and Chair, Pediatrics

The Department of Pediatrics strongly advocates excellence in medical education, health care delivery (service), and research. Its mission is to improve the health of pediatric patients through innovation and leadership. The Department's dedicated faculty are committed to incorporate the newly acquired knowledge into the clinical care of Hawai'i's children and incorporate the findings into the medical school's curriculum that train the next generation of skilled, compassionate, and socially responsible physicians.

The Department of Pediatrics consists of 68 board-certified in Pediatrics faculty. The majority are also certified in Pediatric subspecialties. The Department has a division in general pediatrics and eight Subspecialty Divisions. The general pediatric division provides general pediatric care at KMCWC, Queen Emma Clinic, Kokua Kalihi Valley Center and Waimanalo Health Center Pediatric Clinics.

The Emergency Medicine Division is responsible for the evaluation and management of more than 18,000 patients per year and is managed by faculty board certified in Pediatric Emergency Medicine.

The Hematology Division is the only hospital-based group providing comprehensive diagnosis, treatment and after-care for pediatric patients with hematological and oncological problems. It cares for 98 percent of the children diagnosed with cancer in Hawai'i.

The Hospitalist Division cares for more than 50 percent of the patients admitted to general pediatrics and provides a significant service to community physicians by managing complex pediatric problems.

The Infectious Disease Division is the only group in Hawai'i that provides advice and consultation in pediatric immunology and pediatric infectious diseases to community physicians.

The Pediatric Rheumatology and the Subspecialty Division provides consultation and direct patient care for pediatric patients with collagen vascular diseases, genetic and surgical diagnosis, renal diseases, neurological, allergy, cardiac and gastrointestinal diseases.

Two of the divisions provide pediatric medical care in the inpatient neonatal and pediatric intensive care units. Both units are the only ones in Hawai'i and the Pacific area capable of providing tertiary care for pediatric patients with life-threatening illnesses.

The pediatric faculty continue to represent the Department at national and international scientific meetings through lectures and presentation of abstracts. In 2004 the faculty published 55 journal articles, 75 abstracts and one book. The recently published Textbook of Pediatrics is case based, geared to the third-year medical students, and constitutes the effort of the majority of the Department of Pediatrics faculty.

Education

The Department is responsible for the education of medical students, residents, fellows, and community physicians. The objective of the residency program is to train physicians in general pediatrics by providing an adequate supply of general pediatricians and subspecialists for the care of children in the community. From 2000 to 2005, 59 residents graduated from the Program, one-third remained in Hawai'i and one third is practicing on the mainland. The remaining third applied for fellowship training either in the JABSOM program or on the mainland. Currently there are three fellowship programs: Neonatology in association with Tripler Hospital, Developmental, Behavioral Pediatrics sponsored by the Maternal and Child Health Bureau, and the Koko'okolu Community Pediatrics Fellowship Program with the Department of Health and Human Services.

Service

The Department's community participation is extensive. Faculty contribute to local and national organizations, such as the Hawai'i Poison Control Center, Hawai'i Safe School Coalition, and Good Beginnings Alliance. In 2004-2005, members of the faculty were associated with 27 local organizations and 58 national committees. They provided expert opinion in issues related to pediatrics. During the same period, 179 hours of continuing medical education were provided in the form of Grand Rounds, state of the art lectures, and Community Pediatrics Research Seminars.

Research

The faculty received 45 grants that totaled over $15 million. Ten of the grants are for training programs, such as the fellowship training programs and 35 are for clinical and basic research.

A variety of research projects are conducted by the faculty. Of note are the awards received for clinical research projects to investigate the epidemiology of Group A Streptococci, the investigation of possible effects of prenatal exposure to methamphetamine on

*See **PEDIATRICS**, p. 28*

HAWAI'I MEDICAL JOURNAL

Risk Factors for Pancreatic Cancer in the Hawai'i – Los Angeles Multiethnic Cohort Study

Ute Nöthlings DrPH and Laurence N. Kolonel MD, PhD

Pancreatic cancer is highly fatal. It ranks fourth among United States cancer deaths, and the five-year survival rate is less than 5%.[1] Almost 32,000 new pancreatic cancer cases were estimated to have occurred in the U.S. in 2004.[2]

Due to the poor prognosis and the minimal impact of conventional treatment methods,[3] it is important to focus on prevention of this disease. So far, cigarette smoking is the only well-established risk factor for pancreatic cancer. Other frequently reported risk factors include family history of pancreatic cancer, a diagnosis of diabetes mellitus, age, gender with higher incidence in men, and ethnicity,[3-7] though the findings have been inconsistent across studies.

Pancreatic cancer is a disease difficult to study in epidemiological settings. Studies based on interviews of cases most often have to rely on proxy informants due to the high fatality rate of the disease. For both the patients themselves, as well as proxies, recall of past exposures, such as diet, may be unreliable. Studies that follow cohorts of healthy subjects over time often yield few cases, because the cancer is relatively rare compared to such sites as lung or colorectum.

The Hawai'i - Los Angeles Multiethnic Cohort Study[8] is an epidemiological study of lifestyle factors and cancer risk. It is composed by five main ethnic groups (African-Americans, Japanese-Americans, Latinos, Native Hawaiians and Caucasians) and enrolled more than 200,000 study participants age 45 to 75 years between 1993 and 1996. All study participants initially completed a self-administered comprehensive questionnaire that included a detailed dietary assessment, as well as sections on demographic factors; body weight and height; lifestyle factors other than diet, including smoking history; history of prior medical conditions, including diabetes mellitus; and family history of cancer, i.e. pancreatic cancer diagnoses in the participants' mother, father, full sisters or brothers.

Due to its unusually large size, the Multiethnic Cohort Study provided the opportunity to examine previously reported risk factors for pancreatic cancer in a prospective setting over a period of about seven years of follow-up.

For this analysis, participants not belonging to one of the five targeted ethnic groups; individuals with missing information on body mass index (BMI), smoking status, prior diagnosis of diabetes mellitus; participants reporting implausible diets, or weights or heights; and prevalent pancreatic cancer cases were excluded. Data on 187,566 participants remained. By linkage of the cohort to the Hawai'i Tumor Registry, the Cancer Surveillance Program for Los Angeles County and the California State Cancer Registry a total of 475 incident exocrine pancreatic cancer cases (ICD-O2 codes C25.0-C25.3 and C25.7-C25.9) were identified. Case ascertainment was complete through December 31, 2001. Incidence rates were standardized to the 2000 U.S. standard population. Multivariate adjusted Cox proportional hazards models using age as the time metric were applied to calculate relative risks (RR) for pancreatic cancer by gender for smoking status, a history of diabetes mellitus or familial pancreatic cancer, and obesity. Person-times were calculated beginning at the date of cohort entry, and ending at the earliest of the date of pancreatic cancer diagnosis, date of death, or December 31, 2001, the closure date for the study. All models were stratified for ethnicity and time on study, to allow for different baseline hazard rates. Further details of the analysis can be found in Nöthlings et al.[9]

Table 1.— Study participants' characteristics in the Multiethnic Cohort Study

	Men	Women
N	85,650	101,916
Cases	246	229
Mean age at cohort entry (years)	60	60
Mean follow-up (years)	7.3	7.5
Ethnicity (%)		
African-American	13.6	19.5
Japanese-American	30.1	27.5
Latino	14.0	21.0
Native Hawaiian	6.9	7.4
Caucasian	25.4	24.6
Smoking status (%)		
Never	29.9	55.6
Former	52.1	30.0
Current	18.0	14.3
History of diabetes mellitus (%)	12.6	11.0
History of familial pancreatic cancer (%)	1.4	1.9
Body mass index (%)		
<25 kg/m^2	43.2	50.0
25 – <30 kg/m^2	42.7	30.8
≥30 kg/m^2	14.1	19.1

Table 1 shows study participants' baseline characteristics. Forty-six percent of the study population was male. More than half of the pancreatic cancer cases occurred in men. Both men and women were on average 60 years of age at enrollment into the study. Japanese-Americans comprised the largest proportion of the study population

in both genders with 30.1 percent in men and 27.5 percent in women. Caucasians were the second largest group, followed by Latinos, African-Americans and Native Hawaiians in both genders. More then 50 percent of women were never smokers, as opposed to about 30 percent of men. Larger proportions of women than men were normal weight (BMI < 25 kg/m2) or obese (BMI ≥ 30 kg/m2).[10]

Pancreatic cancer incidence rates for African-American men and women were higher than those for Caucasian men and women. Among men, African-Americans had the highest rate of pancreatic cancer, whereas Native Hawaiians had the highest rate among women (data not shown).

Table 2.— Risk factors for pancreatic cancer in the Multiethnic Cohort Study

	Men		Women	
	RR[i]	95% CI[ii]	RR	95% CI
Smoking status				
Never smokers	1	Ref.	1	Ref.
Former smokers	0.76	(0.62; 0.92)	1.44	(1.18; 1.76)
Current smokers	1.28	(1.01; 1.64)	2.52	(2.01; 3.16)
History of diabetes mellitus	1.50	(1.21; 1.88)	1.27	(0.99; 1.62)
Family history of pancreatic cancer	2.48	(1.57; 3.93)	3.09	(2.17; 4.39)
Body mass index				
< 25 kg/m^2 (normal weight[iii])	1	Ref.	1	Ref.
25 - <30 kg/m^2 (overweight)	1.08	(0.89; 1.31)	0.78	(0.63; 0.96)
≥ 30 kg/m^2 (obese)	1.56	(1.20; 2.03)	1.01	(0.78; 1.29)

i. Relative risks, adjusted for age at cohort entry and all other risk factors in the table
ii. 95% Confidence interval
iii. as defined by WHO[10]

The RR for the selected risk factors and pancreatic cancer for men and women in the Multiethnic Cohort Study are shown in Table 2. Current smokers of both genders were at increased risk for pancreatic cancer. The risk was higher in women [RR = 2.52 (95% CI 2.01-3.16)] than men [RR = 1.28 (95% CI 1.01-1.64)]. Women who quit smoking before enrollment into the study also had an increased risk for pancreatic cancer in contrast to men who quit smoking. A history of diabetes mellitus was associated with increased pancreatic cancer risks in both genders. A history of familial pancreatic cancer was the strongest risk factor in both men and women with a 2.5- and 3-fold increase in pancreatic cancer risk, respectively. Obese men, but not obese women had an increased risk of pancreatic cancer. The increase in risk was about 60 percent for men.

In general, these findings of the Hawai'i - Los Angeles Multiethnic Cohort Study correspond to previous findings in the literature. Pancreatic cancer incidence rates have been reported to be higher in men than women, and higher in African-Americans and Native Hawaiians than Caucasians.[4;11] Our findings support these results, since the pancreatic cancer incidence rate in the Multiethnic Cohort Study was higher in men than in women and incidence rates for African-Americans of both genders were higher than the incidence rate among Caucasians. For Native Hawaiians, the incidence rate among women exceeded that in Caucasian women, but Native Hawai'ian men had a lower incidence rate than Caucasian men.

As expected, smoking was associated with an increased pancreatic cancer risk in the study. The positive association was more pronounced in women than men. A Japanese study recently reported RR of 1.6 and 1.7 for pancreatic cancer in currently smoking men and women in contrast to never smokers, respectively.[12] A study among women in the US found an increased RR of 2.35 for currently smoking women.[13]

The associations between diabetes mellitus and risk for pancreatic cancer have been investigated in various studies. Two meta-analyses calculated increased risks with summary RR of 2.1[14] and 1.8[15]. The differentiation by gender showed a RR of 1.70 for men and 1.57 for women in the latter study.[15] About a 50% increase in pancreatic cancer risk, similar in both genders, was found in one prospective study,[16] another study reported a 4-fold increase in risk,[17] and a further study found a gender difference with a RR of 2.12 for men and 1.50 for women.[18] Confirming these prior investigations, the associations between a history of diabetes mellitus and pancreatic cancer were positive for both genders in the Multiethnic Cohort, though the magnitude of the associations was somewhat smaller than in previous studies.

Family history of pancreatic cancer turned out to be a strong risk factor for pancreatic cancer in the Multiethnic Cohort. This confirmed associations reported in the literature of excess pancreatic cancers in case relatives in comparison to control relatives,[19] and a higher observed-to-expected rate of pancreatic cancer in study participants with at least one pair of first-degree relatives with pancreatic cancers than study participants with none.[20]

The results of studies investigating obesity as a risk factor for pancreatic cancer have been inconsistent so far. A recent meta-analysis based on six case-control and eight cohort studies, however, estimated a summary RR of 1.02 which was statistically significant.[21] The stratification by gender revealed a slightly higher RR for men, which was statistically significant, whereas the RR for women was only of borderline significance. The analysis of the Multiethnic Cohort Study showed a gender effect, with an elevated pancreatic cancer risk in obese men, but not obese women. The magnitude of the effect in men was somewhat higher than the summary measure in the meta-analysis.

Overall, this analysis of the Multiethnic Cohort Study has confirmed most of the risk factors for pancreatic cancer that have been discussed in the literature to date. Smoking, a history of diabetes mellitus, and familial pancreatic cancer were positively associated with pancreatic cancer risk in both genders, whereas obesity was associated with an increased risk in men only.

For more information on the Cancer Research Center of Hawai'i, please visit our website at www.crch.org.

References

1. Jemal A, Clegg LX, Ward E, Ries LA, Wu X, Jamison PM et al. Annual report to the nation on the status of cancer, 1975-2001, with a special feature regarding survival. Cancer 2004; 101(1):3-27.
2. Cancer facts & figures 2004. American Cancer Society, editor. 2004. Atlanta, GA.
3. Li D, Xie K, Wolff R, Abbruzzese JL. Pancreatic cancer. Lancet 2004; 363(9414):1049-1057.
4. Ghadirian P, Lynch HT, Krewski D. Epidemiology of pancreatic cancer: an overview. Cancer Detect Prev 2003; 27(2):87-93.
5. Lowenfels AB, Maisonneuve P. Epidemiology and prevention of pancreatic cancer. Jpn J Clin Oncol 2004; 34(5):238-244.
6. Vimalachandran D, Ghaneh P, Costello E, Neoptolemos JP. Genetics and prevention of pancreatic cancer. Cancer Control 2004; 11(1):6-14.

7. Wang F, Herrington M, Larsson J, Permert J. The relationship between diabetes and pancreatic cancer. Mol Cancer 2003; 2(1):4.
8. Kolonel LN, Henderson BE, Hankin JH, Nomura AM, Wilkens LR, Pike MC et al. A multiethnic cohort in Hawai'i and Los Angeles: baseline characteristics. Am J Epidemiol 2000; 151(4):346-357.
9. Nöthlings U, Wilkens LR, Murphy SP, Hankin JH, Henderson BE, Kolonel LN. Meat and fat intake as risk factors for pancreatic cancer: the multiethnic cohort study. J Natl Cancer Inst 2005; 97(19):1458-1465.
10. Physical status: the use and interpretation of anthropometry: report of a WHO Expert Committee. 1995.
11. Edwards BK, Brown ML, Wingo PA, Howe HL, Ward E, Ries LA et al. Annual report to the nation on the status of cancer, 1975-2002, featuring population-based trends in cancer treatment. J Natl Cancer Inst 2005; 97(19):1407-1427.
12. Lin Y, Tamakoshi A, Kawamura T, Inaba Y, Kikuchi S, Motohashi Y et al. A prospective cohort study of cigarette smoking and pancreatic cancer in Japan. Cancer Causes Control 2002; 13(3):249-254.
13. Harnack LJ, Anderson KE, Zheng W, Folsom AR, Sellers TA, Kushi LH. Smoking, alcohol, coffee, and tea intake and incidence of cancer of the exocrine pancreas: the Iowa Women's Health Study. Cancer Epidemiol Biomarkers Prev 1997; 6(12):1081-1086.
14. Everhart J, Wright D. Diabetes mellitus as a risk factor for pancreatic cancer. A meta-analysis. JAMA 1995; 273(20):1605-1609.
15. Huxley R, Ansary-Moghaddam A, Berrington dG, Barzi F, Woodward M. Type-II diabetes and pancreatic cancer: a meta-analysis of 36 studies. Br J Cancer 2005; 92(11):2076-2083.
16. Calle EE, Murphy TK, Rodriguez C, Thun MJ, Heath CW, Jr. Diabetes mellitus and pancreatic cancer mortality in a prospective cohort of United States adults. Cancer Causes Control 1998; 9(4):403-410.
17. Batty GD, Shipley MJ, Marmot M, Smith GD. Diabetes status and post-load plasma glucose concentration in relation to site-specific cancer mortality: findings from the original Whitehall study. Cancer Causes Control 2004; 15(9):873-881.
18. Lin Y, Tamakoshi A, Kawamura T, Inaba Y, Kikuchi S, Motohashi Y et al. Risk of pancreatic cancer in relation to alcohol drinking, coffee consumption and medical history: findings from the Japan collaborative cohort study for evaluation of cancer risk. Int J Cancer 2002; 99(5):742-746.
19. Ghadirian P, Liu G, Gallinger S, Schmocker B, Paradis AJ, Lal G et al. Risk of pancreatic cancer among individuals with a family history of cancer of the pancreas. Int J Cancer 2002; 97(6):807-810.
20. Klein AP, Brune KA, Petersen GM, Goggins M, Tersmette AC, Offerhaus GJ et al. Prospective risk of pancreatic cancer in familial pancreatic cancer kindreds. Cancer Res 2004; 64(7):2634-2638.
21. Berrington dG, Sweetland S, Spencer E. A meta-analysis of obesity and the risk of pancreatic cancer. Br J Cancer 2003; 89(3):519-523.

***PEDIATRICS**, from p. 25*

child development, and training program geared to understand the possible reasons for health disparities in Hawai'i's communities. Basic research is an integral part of the department's commitment with studies such as: effects of Dexamethasone on the development of the stress axis in the rat brain (sponsored by the NIH); cellular mechanism on lung growth (sponsored by the Leahi Foundation), and the role of HIV in AIDS associated with dementia (sponsored by the NIH-NCRR).

The Future

The Department of Pediatrics is young and continues to grow and develop like a healthy child. The goals are to be one of the best pediatric departments in the U.S., to further solidify association with community partners, and to provide the best possible care to the children of Hawai'i.

Tons of training...
Long Hours...
Short on time.

I've been there.

- Experienced working with physicians in realty.
- Experienced working with physicians in hospitals… I'm an RN.
- Experienced working with physicians at home… I'm married to one.

I understand.

The Physician's Real Estate Specialist.
Cori Hamilton, RN, RA, ABR, CRS
(808) 375-3959

RE/MAX Kai Lani 25 Kaneohe Bay Drive #109, Aikahi Shopping Center Kailua, HI 96734
Each RE/MAX office independently owned and operated.

"Tell me where it hurts."

At Hawaii National Bank, we've got just the *remedy* for costly expenditures.

Specialized loan programs for Medical Professionals like you!

Preferred rates and terms provide you with the *flexibility* to expand or renovate. Stay on the cutting edge of your profession with a little help from your Warm-Hearted Bankers.

Rx
"where your professional business comes first"
www.HawaiiNational.com
528-7711

HAWAII NATIONAL BANK

Classified Notices

To place a classified notice:

HMA members.–As a benefit of membership, HMA members may place a complimentary one-time classified ad in HMJ as space is available.

Nonmembers.–Rates are $1.50 a word with a minimum of 20 words or $30. Not commissionable.

For more information call (808) 536-7702.

Space for Lease

WAHIAWA — FINISHED OFFICE /CLINIC SPACE FOR LEASE, ground floor in prestige medical building: 750 sf to 6,000 sf. Central a/c, parking. Suzie: 627-0824.

Even the smallest ads are seen in the Hawai'i Medical Journal.
To place a classified ad call 536-7702.

Take your business to the next level and offer:

- ***Credit Card Acceptance***
- ***Personalized Gift Cards***
  (First 100 Cards FREE with this promotion)
- ***PIN-Secured Debit and more***

Open a new merchant account with West Coast Merchant Services and benefit from a broad range of products and services that will add value to your business.

Through our relationship with First Data, West Coast Merchant Services is able to provide you specifically tailored merchant programs to meet your business needs. First Data is a world leader in point-of-sale payment processing with over 3 million merchant locations.

MERCHANT ACCOUNT BENEFITS!

- 100 gift cards plus everything you need to start selling gift cards
- The TeleCheck Electronic Check Acceptance® (ECA®) for faster, more secure processing
- Free online reporting (including paperless statements) with the MyMerchantView® Online Service
- Local account representatives to answer your questions



WEST COAST MERCHANT SERVICES

Call Today! Angela Devargas
808-398-0007

FIRST DATA

Payment Services • Merchant Services • Card Services • Debit/ATM Services • Risk Management

Making global commerce happen.

©2005 First Data Merchant Services Corporation. All rights reserved. All trademarks, service marks and trade names referenced in this material are the property of their respective owners.

Kuakini Physicians Tower

For Sale (Leasehold)
Medical Office Condo
Units available from 652 to 1,527 sq. ft.

Prices starting at $126,500
Design your ideal office space
or
Lease a finished office space
Lease Rents from $2.40 psf
+ utilities and parking

Craig Nakamura (PB)
Commercial Properties Of Honolulu
591-8755
Peter M. Lee (R)
Marcus & Associates, Inc.
839-7446

HAWAI'I MEDICAL JOURNAL

❖ WHAT DO YOU MEAN BOGUS VACCINE? I MADE IT MYSELF THIS AFTERNOON.

The event could have been taken from a *Law and Order* television script. In Houston, Texas, as many as 1,000 people have been injected with a make-believe flu vaccine. The owner and manager of Comfort and Caring Home Health in Houston, Texas, provided fake flu vaccine for more than 1,000 Exxon employees at a health fair, as well as 14 patients at his home care facility. A contract nurse became suspicious when she heard employees complaining about having to stay up all night filling syringes. She noted that the employees had no knowledge of lot numbers used to track vaccines, so she notified authorities. The FBI seized 32 syringes for analysis which were found to contain "some form of purified water" according to the FDA. If found guilty, the man could face 10 years in federal prison and a fine of $250,000.

❖ IF THINGS SEEM TO BE GOING WELL, YOU HAVE OVERLOOKED SOMETHING.

A 6-year-old boy with a benign brain tumor had successful cranial surgery and was recovering well. During a follow-up MRI, an attendant brought an unsecured oxygen tank into the room. The tank, about the size of a fire extinguisher, was caught in the powerful magnetic field, flew rapidly into the chamber, struck the child in the head and caused his death. According to the FDA's Manufacturer and User Facility Device Experience (MAUDE) only 389 MRI incidents of deaths and injuries have been reported in the last 10 years. Most of the deaths were failure of pacemakers or insulin pumps, and injuries were burns, projectiles, and implant problems. This number (389) is considered very small since 10 million patients are scanned annually, but experts doubt these numbers since MAUDE only requires reporting "serious" incidents. When Pennsylvania required mandatory reporting of all incidents, data were gathered over 16 months and 88 MR events occurred, which fortunately were "near misses" with no patient injuries (flying chairs, stools, etc). Emanuel Kanal, MD, director of MR services and professor of neuro-radiology at University of Pittsburgh Medical Center, estimates that the FDA data base records less than 10 percent of MR incidents and less than half of all deaths.

❖ IF AT FIRST YOU DO SUCCEED , WHAT ARE YOU USING?

Every competitive athlete is looking for a legitimate way to get an edge, and testimonials from prominent athletes have endorsed lasik surgery. To determine real or imagined improvement, Daniel Laby, MD, associate clinical professor at Harvard and David Kirschen, O.D. PhD at UCLA evaluated a dozen baseball players who had undergone lasik surgery. As might be predicted, performance at bat was not improved following the operation. The investigators recommended that due to the possibility of career ending complications, athletes should wait until retirement from competitive sports before considering a surgical procedure. Despite technical magic, the best route to the hall of fame at Cooperstown or Canton, Carnegie Hall or Nashville is practice, practice, practice.

❖ IT'S NOT SPEED, HORSE, POT, ACID OR HASH. IT'S JUST GREAT MUSIC.

And on the subject of getting an edge, baseball purists clamor for steroid-using Barry Bonds, Mark McGwire, Rafael Palmeiro, Jason Giambi et al., to give back their awards. But what about concert musicians! Thirty years ago in the 1970s a tuba-playing vascular surgeon tried prescribing a beta blocker to calm down nervous musicians with stage fright. It worked, and in a very short time nervous musicians became users. Normally prescribed for vascular disease, the drug slows the pulse and lowers blood pressure. According to a 1987 study of 51 major concert orchestras, every fourth musician was using a beta blocker. Seventy percent get the drug illicitly. Does the artistic world care? Not even a little bit. Beta-blockers are banned by the *World Anti-Doping Agency* from everything from curling to bobsledding (and even chess), but the musical world apparently could not care less. Whatever complaints exist stop outside concert hall, and how do you measure a concert musician's performance anyway? Ladeda and tralala.

❖ WHY IS THE CAPTAIN CARRYING A WHITE CANE?

Researchers at the University of Iceland in Reykjavik studied 445 men age fifty and beyond regarding the incidence of lens opacities. Surprisingly, 71 of the 79 with cataracts were pilots. The interpretation is that exposure to cosmic rays while high in the sky, increases the risk of developing cataracts. They also found an association with smoking and sunbathing. Previously it has been reported that astronauts have a higher risk of premature lens opacities. So, fly low, refrain from lounging at the pool or seaside, eschew tobacco, wear good sunglasses, stay away from steroids, and carefully select your genes. You might be boring, but you will see better.

❖ IF YOU THINK THERE IS GOOD IN EVERYBODY, YOU HAVEN'T MET EVERYBODY!

In Minnesota, Blue Cross/Blue Shield elected to financially penalize physicians who choose to hospitalize their patients at hospitals the Blues consider too costly. Doctors who refused to sign an agreement to refer to cheaper hospitals would automatically be placed on a "least desirable" list and their patients obligated for higher out of pocket costs. The Minnesota Medical Society jumped in with the argument that ranking physicians and hospitals on the basis of cost should not be considered without also evaluating quality of medical care. The Blues backed off, which probably only means they will seek another mechanism to twist physicians' arms. Ranking hospitals according to cost is not rare on the Mainland, but unheard of in Hawai'i.

❖ AGAINST LOGIC THERE IS NO ARMOR LIKE IGNORANCE.

The ubiquitous human papilloma virus that causes genital warts can be controlled. Both Merck and Glaxo-Smith Kline are ready to market a vaccine which they claim will give 100 percent protection. It is extremely important because the virus infection is linked to cervical cancer, which kills 3,700 American women each year, and many thousands more world wide. It is a very subtle infection spread by sexual contact, and there may be no signs or symptoms. Both sexes can unknowingly carry the virus. Should the vaccine be given to grade school children along with standard childhood immunizations to produce 100 percent immunity? One might think this is a no-brainer, but not to conservative religious parties in the Bush camp. They argue that a vaccine designed to prevent a sexually transmitted disease will sabotage their abstinence message, and encourage young people to have pre-marital sex. Nonsense, say vaccine advocates. "Does wearing a seat belt mean you intend to have a crash?" How the vaccine will be used will be determined largely by the *Advisory Committee on Immunization Practices*, a panel of experts assembled by the Centers for Disease Control and Prevention (CDC).

❖ WHO IS THAT, GERONIMO OR ROBIN HOOD?

In Montclair, California, a freight train was stopped to let another train pass. A man jumped on the train with a bow and arrow and threatened the two-man crew. The crew immediately bailed out and ran, but the alert engineer closed the throttle as he left, essentially stranding the train. Police were called and shot the man (no serious injury) when he pointed his weapon at an officer. Zounds! What to charge him with besides threatening with a deadly weapon? The DA decided on car-jacking since the train has a diesel engine and was towing 70 cars.

❖ MACABRE, SPECTRAL, WEIRD, EERIE -- IT'S JUST HALLOWEEN! OR IS IT?

It was October 31 in Frederica, Delaware. When police received a call about a body hanging from a tree fifteen feet over a road, they rolled their eyes. Assuming it was a Halloween trick they took their time arriving on the scene. Surprise! It was not a dummy at all, but a real woman who had been hanging for hours. Passing motorists and pedestrians thought some pranksters were at play and failed to call until someone punched in nine one one.

ADDENDA

- ❖ 2,000 teenage smokers become newly addicted to tobacco every day. Thank you Philip Morris, et al.
- ❖ San Francisco cable cars are the only rolling National Monuments.
- ❖ Coca-Cola was originally green.
- ❖ Don't suffer from stress. Be a carrier!

ALOHA AND KEEP THE FAITH — **rts**■

Contents of this column do not necessarily reflect the opinion or position of the Hawaii Ophthalmological Society and the Hawaii Medical Association. Editorial comment is strictly that of the writer.

Did you know all of these are reportable diseases?

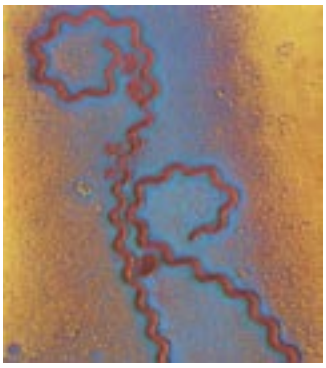

Leptospirosis

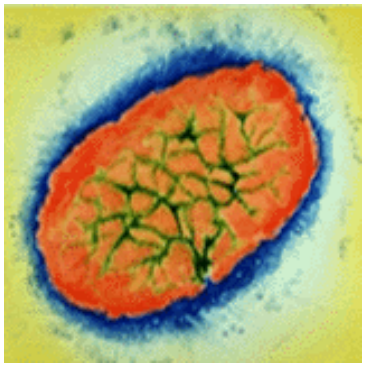

Pertussis

Salmonellosis

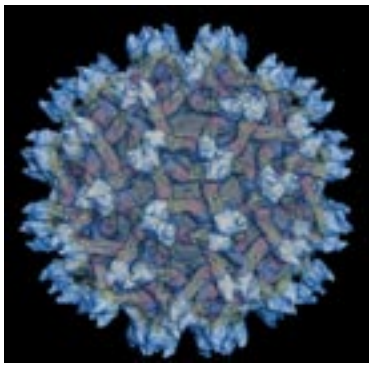

Dengue Fever

These are just a few of the infectious diseases that health care providers in Hawaii are required to report.

To report an infectious disease *or* outbreak, call

Department of Health
Disease Outbreak Control Division

Oahu: (808) 586-4586
Maui: (808) 984-8213
Kauai: (808) 241-3563
East Hawai'i: (808) 933-0912
West Hawai'i: (808) 322-4877

For the most current information, visit the Department of Health website:
www.hawaii.gov/health/about/rules/rules/11-156.pdf

Hawaii State Department of Health

Professional Liability Insurance

MIEC is your bridge to safety

THE PROFESSIONALS AT MIEC KNOW WHAT PHYSICIANS WANT—malpractice insurance with competitive rates, outstanding underwriting and claims service, and an excellent loss prevention program. This assurance of a "bridge to safety" was the founding premise of the original policyholder-owners back in 1975. And we think it's the reason most of our policyholders choose to stay with MIEC throughout their career.

Let us tell you more about our coverages and service. Call us for an application kit at 800-227-4527, or get an instant premium quote on-line at **www.miec.com**.

Medical Insurance Exchange of California
6250 Claremont Avenue, Oakland, California 94618 800-227-4527
www.miec.com

Hawaii claims office: 1360 South Beretania Street, Honolulu, Hawaii 96814