

A Metal-Associated Epithelioid Angiosarcoma: A Case Report and Literature Review

Sean Chan, MD¹, Jonathan Horng, MD¹, Morgan E Hasegawa, MD¹, Sean Saito, MD², Julian B Rimm, MD, MS¹, Koah Vierkoetter, MD², Morris Mitsunaga, MD¹

¹ Department of Surgery, Division of Orthopaedics, University of Hawai'i John A Burns School of Medicine, ² Department of Pathology, University of Hawai'i John A Burns School of Medicine

Keywords: Angiosarcoma, epithelioid angiosarcoma, orthopedic implants, Neoplasm

<https://doi.org/10.62547/MOZH2737>

Abstract

Angiosarcoma is a rare, aggressive malignancy that accounts for less than 1% of sarcomas of bone. Epithelioid angiosarcoma, a subtype, is characterized by pleomorphic cells with vascular differentiation and commonly arises in deep soft tissues of the extremities. Angiosarcoma associated with orthopedic implants or retained foreign bodies, such as ballistic debris, is exceedingly rare. Here, the authors present the case of epithelioid angiosarcoma in a 54-year-old male with a history of a prior proximal femur ballistic injury and intramedullary nail fixation who was initially misdiagnosed with chronic osteomyelitis.

Introduction

Angiosarcoma is a rare and aggressive malignancy which accounts for less than 1% of sarcomas of the bone.^{1,2} Epithelioid angiosarcoma is a subtype that has also been found in diverse primary sites throughout the body, but most commonly arises from deep soft tissue locations in the extremities.³⁻⁵ Prognosis for angiosarcoma of the bone is overall poor, with median survival rates reported to range from 9-16 months; however, some subsets of patients have more favorable prognosis, with protective factors including stage of cancer upon presentation, age under 50, and surgical treatment.^{2,6} Histologically, the epithelioid subtype of angiosarcoma is characterized by large, pleomorphic round cells with prominent nucleoli and high mitotic activity, organizing in sheets and focal areas of vessel formation with irregular anastomoses which can be demonstrated on hematoxylin-eosin staining.⁴ Angiosarcoma arising in relation with retained foreign bodies, including orthopedic implants such as intramedullary nails and total joint arthroplasty components, is rare but has been reported in both orthopedic surgical and pathology literature.^{5,7,8}

Case

Patient is a 54-year-old male who initially presented to the emergency department with left groin, hip, and thigh pain and orthopedic consultation was requested for concerns of left proximal femur osteomyelitis. Patient reported pain had begun 6 months prior. Work up by various health care professionals attributed his symptoms to adductor muscular strains, osteoarthritis, and trochanteric bursitis. He was prescribed NSAIDs and given a steroid injection to left hip.

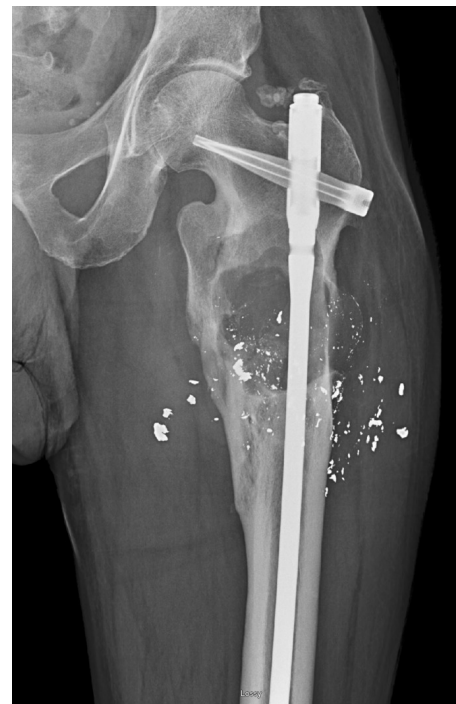

Figure 1. Radiograph of the left femur, demonstrating a cephalomedullary nail *in situ*, bullet fragments, and a remote subtrochanteric femur fracture with lytic changes

There was some relief, but symptoms persisted. He was referred to an orthopaedic clinic where labs demonstrated leukocytosis and elevated inflammatory markers. The patient's pertinent past medical history included a remote open left subtrochanteric femur fracture after ballistic injury, which was sustained approximately 30 years prior and initially treated with a cephalomedullary nail.

At that time of initial assessment, he endorsed subjective fevers and chills. Plain films demonstrated the pre-existing cephalomedullary nail, ballistic debris, as well as an age-indeterminate proximal diaphyseal lytic lesion (Figure 1). Nuclear medicine bone scan redemonstrated the lytic lesion, also showing local soft tissue involvement (Figure 2). CT guided biopsy was suggestive of acute osteomyelitis. He elected for conservative management with IV antibiotics and was discharged with an appropriate antibiotic plan.

Symptoms initially improved some, but he presented again 1 month later with exacerbation of pain. Magnetic resonance imaging (MRI) was obtained and demonstrated a

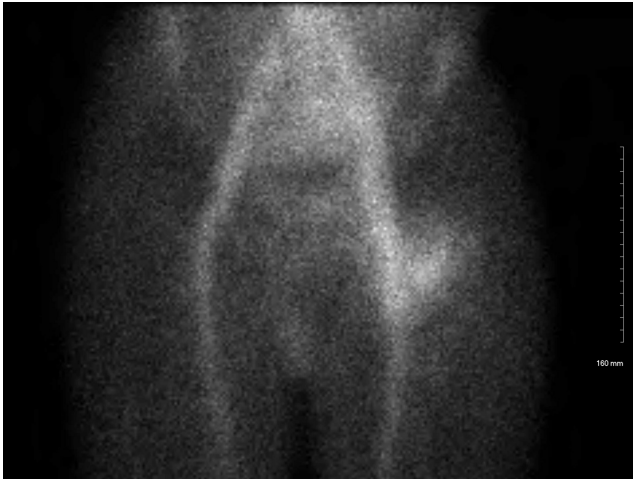

Figure 2. Nuclear medicine bone scan showing increased soft tissue and bone reactivity at the left proximal femur

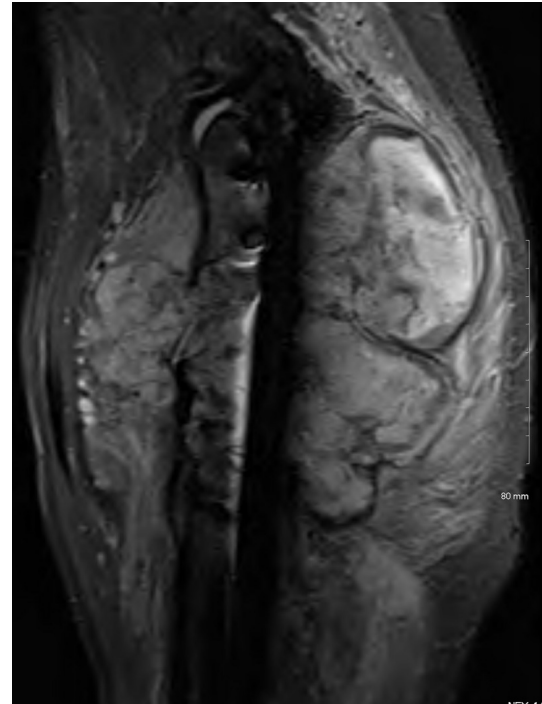


Figure 3b. MRI (fat suppressed) of the left proximal femur, sagittal

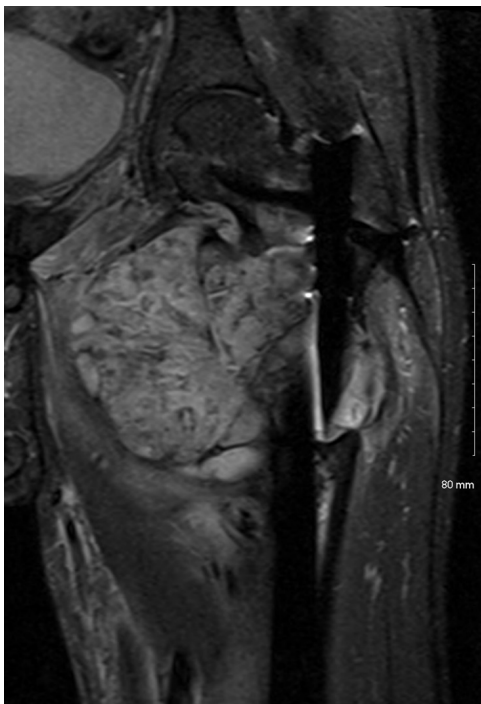

Figure 3a. MRI (fat suppressed) of the left proximal femur, coronal

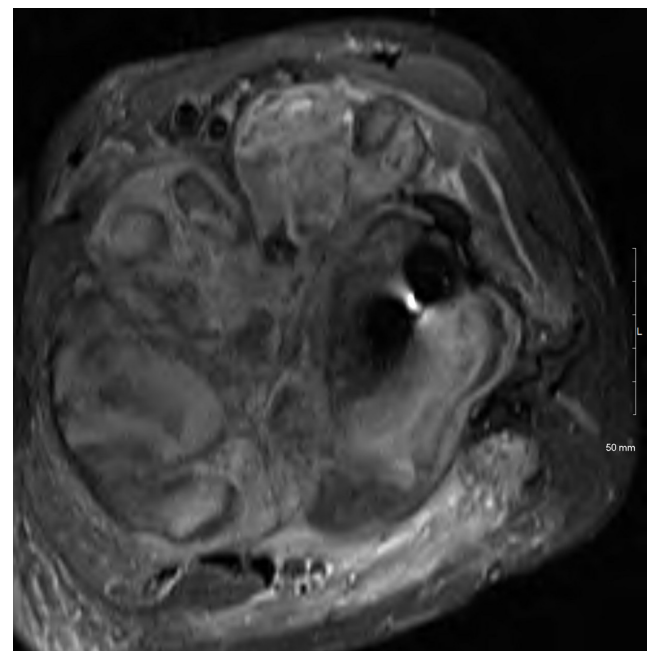


Figure 3c. MRI (fat suppressed) of the left proximal femur, axial

13.4 cm x 140 cm x 13.6 cm lobulated, heterogeneous, destructive mass in the proximal femur with osseous destruction and soft tissue infiltration into the anterior, posterior, and adductor compartments ([Figure 3](#)). The sciatic nerve was displaced posteriorly but not encased by the mass. Inguinal lymphadenopathy and flow voids within the femoral vascular structures were also noted. Repeat nuclear medicine bone scan redemonstrated abscess and osteomyelitis.

The patient subsequently underwent hardware removal, debridement, intramedullary biopsies, and revision cephalomedullary nail fixation. Gross examination of the intramedullary samples demonstrated aggregates of clotted

blood and bone totaling a size of 5.1 cm x 3.8 cm x 0.5 cm. The explanted hardware was unremarkable. Microscopically, the intramedullary biopsies were determined to be a high-grade malignancy with vascular differentiation, consistent with epithelioid angiosarcoma. There was positive immunohistochemical expression of CD31, ERG, cytokeratin AE1/AE3, and cytokeratin 8/18 ([Figure 4](#)); and nega-

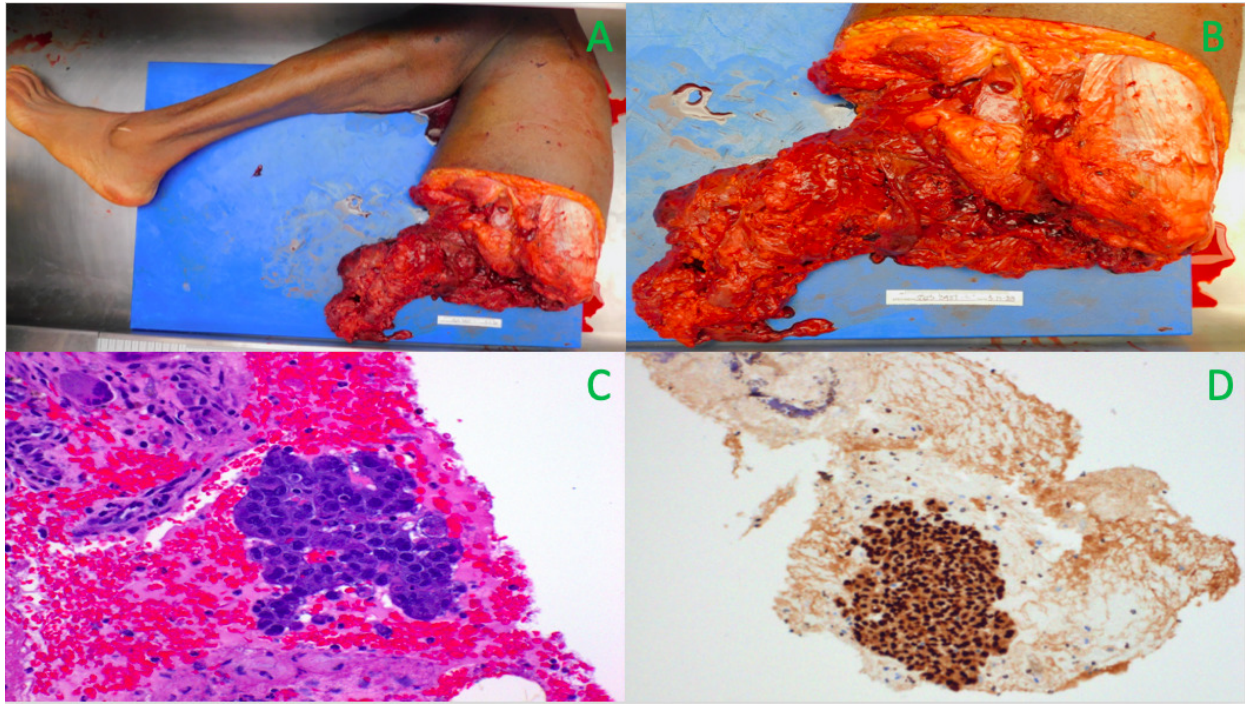


Figure 4. Gross image of left leg with tumor (A&B). Microscopic section of viable tumor cells, Hematoxylin-Eosin stain (C). Tumor cells showing positive immunohistochemical expression for ERG (D).

tive for S100, SOX100, GATA3, NKX3.1, TTF1, PAX8, CDX2, p40, HHV8, and CD34.

Whole body PET/CT scan demonstrated a hypermetabolic lesion to the left proximal thigh. There was no evidence of regional or distant metastatic disease. The tumor was staged as Stage III T2N1M0 epithelioid angiosarcoma. The patient was started on neoadjuvant gemcitabine/docetaxel with intent of limb salvage and completed the course. However, after additional consultation with medical and orthopedic surgical oncology, the limb was deemed unsalvageable and the patient ultimately underwent hip disarticulation.

Gross examination of the specimen revealed an irregular gray-white hemorrhagic mass in the proximal thigh with extension into the surrounding soft tissues measuring 18 cm x 9 cm x 7 cm (Figure 4). The proximal margin was negative and microscopically there was 99.9% necrosis of the tumor and 0.1% viable tumor, indicating positive treatment effect. Three regional lymph nodes were negative for tumor.

The patient developed post-operative anemia and surgical site hematoma, which was surgically evacuated. Cultures were positive for *Pseudomonas aeruginosa*, vancomycin-resistant *Enterococcus faecium*, *Escherichia coli*, and *Eubacterium limosum*. The patient was started on appropriate antibiotic therapy and underwent serial debridements. The wound eventually healed well with negative cultures.

Discussion

This is a case of ballistic fragment associated epithelioid angiosarcoma in 54-year-old male with a remote history of ballistic left subtrochanteric femur fracture treated with

a cephalomedullary device. Metal induced epithelioid angiosarcoma has been described in the literature in association with metal orthopedic implants,⁹⁻¹⁶ however, to the authors' knowledge, this is the first report of musculoskeletal epithelioid angiosarcoma associated with retained ballistic fragments.

Per McDonald and Enneking,⁹ 3 criteria must be met to establish the diagnosis of metal-associated sarcoma. First, the tumor must be in the direct vicinity of a metallic implant in bone or soft tissue, which excludes lesions that occur in the general region of the implant or a more distant site in the same extremity. Second, the tumor should develop after a latency of around 2 years or more, as a tumor identified within one-year of placement of an implant likely was present before surgery at an unrecognizable stage. Third, there should be no other obvious, well-recognized factor predisposing the development of a secondary malignancy, such as radiation or chronic infection. The most significant factor of the current case that opposes these criteria is the presence of chronic osteomyelitis, which has been implicated in carcinogenesis. As such, metal implant associated sarcoma is less likely implicated in this case based on these criteria. Another confounder to these criteria and potential carcinogenic factor in the current case is the presence of retained ballistic fragments. Though the literature is sparse, there are several cases of musculoskeletal ballistic fragment associated malignancy reported in the literature.^{15,16}

Ebrahimzadeh and colleagues described 2 cases in which musculoskeletal malignancies developed near retained war shells over 20 years after initial injury.¹⁷ In the first case, a 44-year-old male developed a low-grade osteosarcoma in the distal femoral metaphysis 22 years after suffering a

gunshot wound with retained ballistics to his thigh. In the second case, a 67-year-old male developed a myxofibrosarcoma in his volar forearm 25 years after suffering a gunshot wound with retained ballistics to his palm and hand. The authors propose that retained ballistics may not be as inert as is historically accepted and a monitoring system should be implemented for patients with known retained ballistics.

Teltzrow et al also report a case of ballistic fragment associated angiosarcoma to the temporal region soft tissues in an 84-year-old man that presented 60 years after the injury.¹⁸ This individual's course was initially complicated by infection and purulent sinus, though the authors did not mention if chronic infection was present at time of resection. The authors postulated that the presence of metal composition may have contributed to carcinogenesis,

though chronic inflammation was their leading etiology for carcinogenesis.

The etiologies of carcinogenesis to consider in the current case include primary malignancy, secondary to chronic osteomyelitis, and/or metal implant associated. Akin to the above cases, retained ballistic fragments may also be implicated in carcinogenesis. Though seemingly rare, health care practitioners should be aware of this potential association between retained ballistic fragments and malignancy.

Submitted: September 11, 2025 PDT. Accepted: October 19, 2025 PDT. Published: June 01, 2026 PDT.

References

1. Palmerini E, Leithner A, Windhager R, et al. Angiosarcoma of bone: a retrospective study of the European Musculoskeletal Oncology Society (EMSOS). *Sci Rep*. 2020;10(1):10853. doi:[10.1038/s41598-020-66579-5](https://doi.org/10.1038/s41598-020-66579-5)
2. Palmerini E, Maki RG, Staals EL, et al. Primary angiosarcoma of bone: a retrospective analysis of 60 patients from 2 institutions. *Am J Clin Oncol*. 2014;37(6):528-534. doi:[10.1097/COC.0b013e31827defa1](https://doi.org/10.1097/COC.0b013e31827defa1)
3. Rouhani P, Fletcher CD, Devesa SS, Toro JR. Cutaneous soft tissue sarcoma incidence patterns in the U.S.: an analysis of 12,114 cases. *Cancer*. 2008;113(3):616-627. doi:[10.1002/cncr.23571](https://doi.org/10.1002/cncr.23571)
4. Hart J, Mandavilli S. Epithelioid angiosarcoma: a brief diagnostic review and differential diagnosis. *Arch Pathol Lab Med*. 2011;135(2):268-272. doi:[10.5858/135.2.268](https://doi.org/10.5858/135.2.268)
5. Agaimy A, Ben-Izhak O, Lorey T, Scharpf M, Rubin BP. Angiosarcoma arising in association with vascular Dacron grafts and orthopedic joint prostheses: clinicopathologic, immunohistochemical, and molecular study. *Ann Diagn Pathol*. 2016;21:21-28. doi:[10.1016/j.anndiagpath.2016.01.002](https://doi.org/10.1016/j.anndiagpath.2016.01.002)
6. Wong A, Flores J. Cutaneous angiosarcoma of the head and neck resembling rosacea: A case report. *SAGE Open Med Case Rep*. 2020;8:2050313X20940419. doi:[10.1177/2050313X20940419](https://doi.org/10.1177/2050313X20940419)
7. Terrando S, Sambri A, Bianchi G, et al. Angiosarcoma around total hip arthroplasty: case series and review of the literature. *Musculoskelet Surg*. 2018;102(1):21-27. doi:[10.1007/s12306-017-0496-6](https://doi.org/10.1007/s12306-017-0496-6)
8. Park JW, Cho HM, Park C, Kim JH, Bong HS. Metal Associated Angiosarcoma of the Distal Femur. *Journal of the Korean Orthopaedic Association*. 2012;47(6):457-462. doi:[10.4055/jkoa.2012.47.6.457](https://doi.org/10.4055/jkoa.2012.47.6.457)
9. Samargandi R. Etiology, pathogenesis, and management of angiosarcoma associated with implants and foreign body: Clinical cases and research updates. *Medicine (Baltimore)*. 2024;103(18):e37932. doi:[10.1097/MD.00000000000037932](https://doi.org/10.1097/MD.00000000000037932)
10. McDonald DJ, Enneking WF, Sundaram M. Metal-associated angiosarcoma of bone: report of two cases and review of the literature. *Clin Orthop Relat Res*. 2002;(396):206-214. doi:[10.1097/00003086-200203000-00031](https://doi.org/10.1097/00003086-200203000-00031)
11. Ferrari D, Pignatti G, Bertoni F, Bacchini P, Giunti A. Angiosarcoma of bone following intramedullary nail fixation. *Orthopedics*. 2001;24(8):795-797. doi:[10.3928/0147-7447-20010801-26](https://doi.org/10.3928/0147-7447-20010801-26)
12. Dube VE, Fisher DE. Hemangioendothelioma of the leg following metallic fixation of the tibia. *Cancer*. 1972;30(5):1260-1266. [https://doi.org/10.1002/1097-0142\(197211\)30:5%3C1260::aid-cncr2820300518%3E3.0.co;2-y](https://doi.org/10.1002/1097-0142(197211)30:5%3C1260::aid-cncr2820300518%3E3.0.co;2-y)
13. Memoli VA, Urban RM, Alroy J, Galante JO. Malignant neoplasms associated with orthopedic implant materials in rats. *J Orthop Res*. 1986;4(3):346-355. doi:[10.1002/jor.1100040311](https://doi.org/10.1002/jor.1100040311)
14. Hughes AW, Sherlock DA, Hamblen DL, Reid R. Sarcoma at the site of a single hip screw. A case report. *J Bone Joint Surg Br*. 1987;69(3):470-472. doi:[10.1302/0301-620X.69B3.3034914](https://doi.org/10.1302/0301-620X.69B3.3034914)
15. Tayton KJ. Ewing's sarcoma at the site of a metal plate. *Cancer*. 1980;45(2):413-415. [https://doi.org/10.1002/1097-0142\(19800115\)45:2%3C413::aid-cncr2820450238%3E3.0.co;2-#](https://doi.org/10.1002/1097-0142(19800115)45:2%3C413::aid-cncr2820450238%3E3.0.co;2-#)
16. Kirkpatrick CJ, Alves A, Kohler H, et al. Biomaterial-induced sarcoma: A novel model to study preneoplastic change. *Am J Pathol*. 2000;156(4):1455-1467. doi:[10.1016/S0002-9440\(10\)65014-6](https://doi.org/10.1016/S0002-9440(10)65014-6)
17. Ebrahimzadeh MH, Vahedi E, Ganji R, Bozorgnia S. Skeletal sarcoma on the site of retained war bullet fragments and a literature review on long-term complications of retained war shells. *Arch Bone Jt Surg*. 2013;1(2):107-111.
18. Teltzrow T, Hallermann C, Müller S, Schwipper V. Foreign bodyinduced angiosarcoma 60 years after a shell splinter injury. *MundKieferGesichtschirurgie*. 2006;10(6):415-418. doi:[10.1007/s10006-006-0026-4](https://doi.org/10.1007/s10006-006-0026-4). PMID:17006674